Head Injury

HEAD INJURY

DEFINITION

- Any trauma that leads to injury of the scalp, skull, or brain.
- The injuries can range from a minor scalp laceration to serious brain injury.

INCIDENCE

- Head injury is the number one Killer in trauma.
- 4 million people experience head trauma annually(WHO).
- 25% of all trauma deaths.
- 50% of all deaths from MVA.

Risk Population

- Males 15-24 years.
- Males / females = 2/1
- Infants & Young Children
- Elderly

Causes

- Motor vehicle accidents
- Falls
- Assaults
- Sports-related injuries
- Firearm-related injuries

MECHANISM

- **BLUNT INJURY**
  - High Velocity
  - Low Velocity

- **PENETRATING INJURY**
  - Gunshot
  - Sharp instruments

Acceleration

- Immobile head is struck by a moving object .
- Skull moves away from force
- Brain rapidly accelerates from stationary to in- motion state causing cellular damage

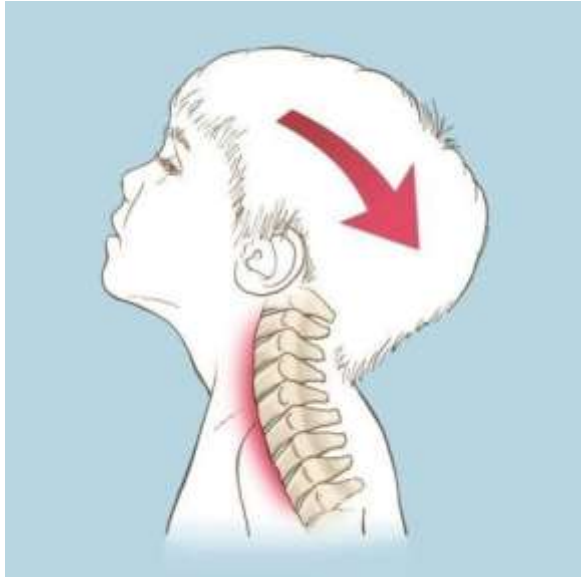

Acceleration

Deceleration

- Head is moving and hits an immobile object
- Brain continues moving in skull towards direction of impact, resulting in significant forces that damage cells

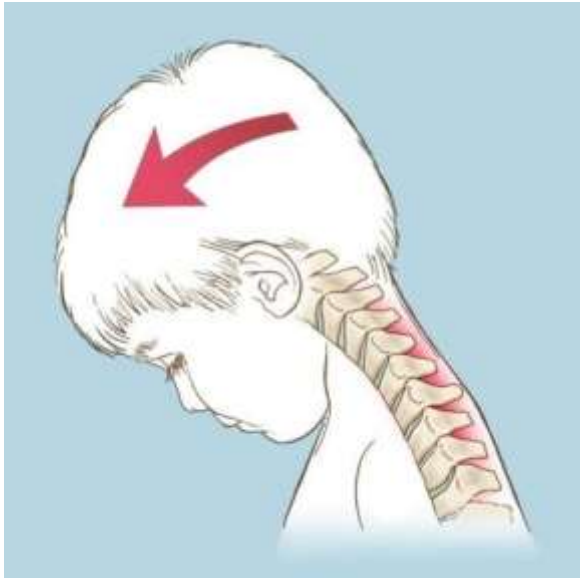

Deceleration

Coup/Contrecoup

Injury resulting from rapid, violent movement of brain

- **Coup**

  Injury at site of impact

- **Contrecoup**

  Injury on opposite side from impact

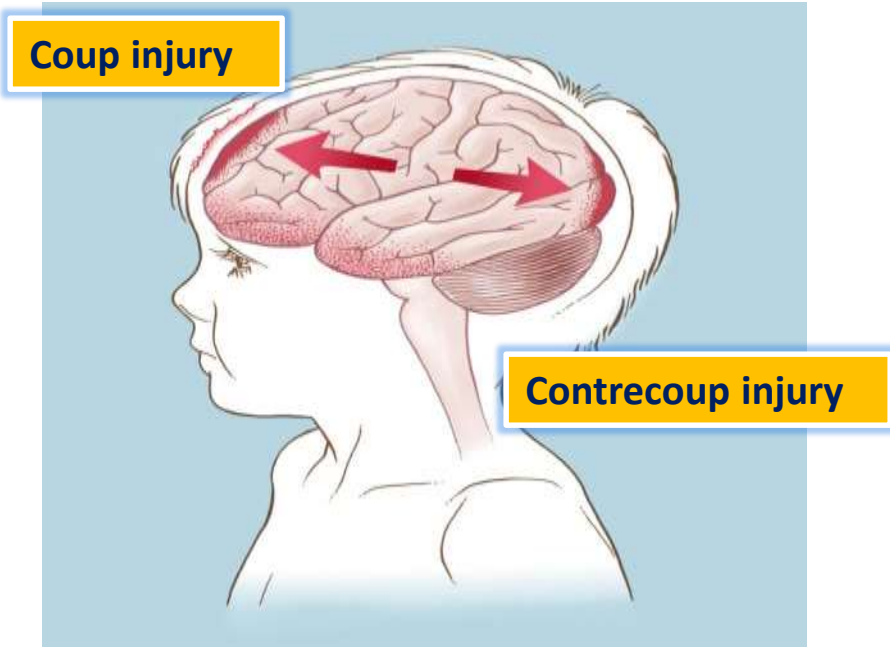

Basic Anatomy

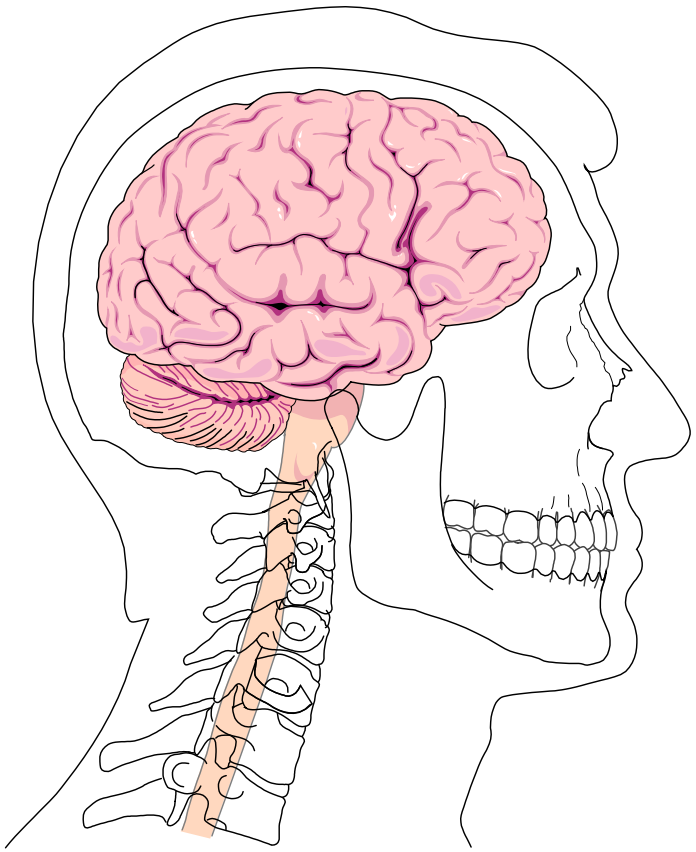

- **Scalp**
- **Skull**
- **Meninges**
  - **Dura Mater**
  - **Arachnoid**
  - **Pia Mater**
- **Brain Tissue**
- **CSF and Blood**

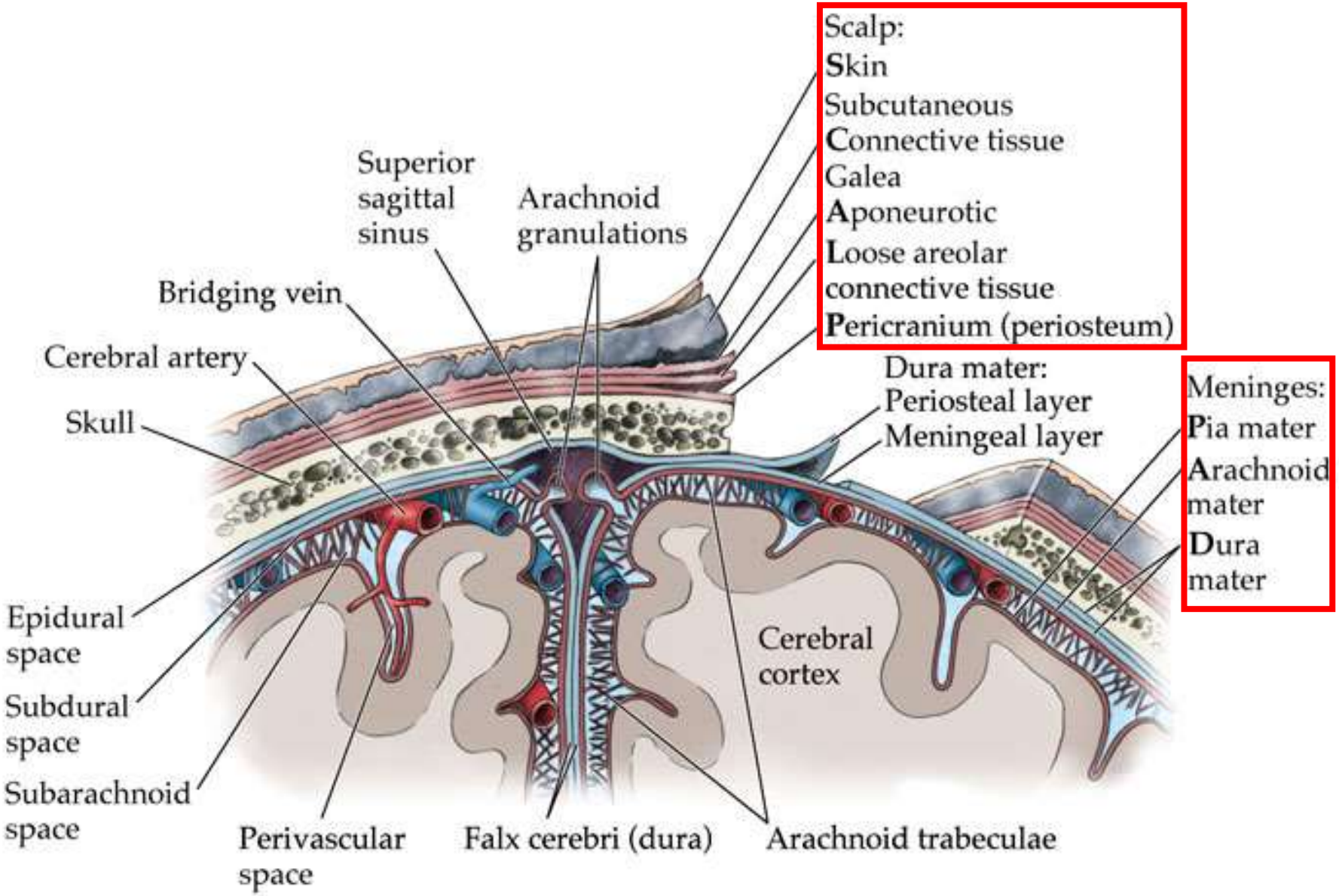

Morphological Classification

Scalp injuries

Skull fractures

Brain injuries

Scalp injury

(1) laceration or bruises (minor injury)

Scalp is highly vascular

(children may develop shock)

Major complication is infection

(2) Scalp hematoma include 3types:

Sub-cutaneous

Sub- galeal

Sub-periosteal

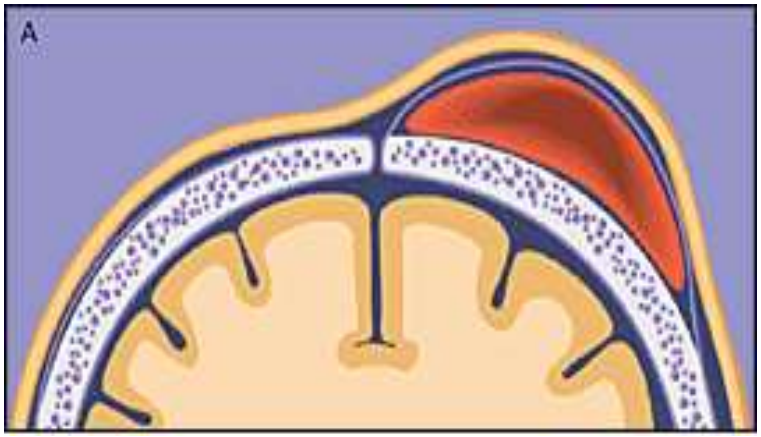

Sub-periosteal Hematoma

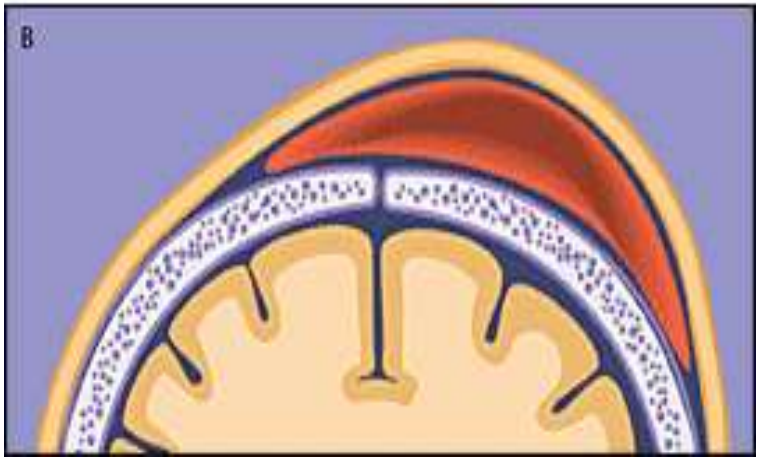

Sub-galeal Hematoma

SKULL FRACTURES

Linear Skull Fracture

- Break in the continuity of the bone.
- Appear as thin lines on X-ray.
- Full thickness through bone.
- Of little significance **<u>except</u>** when it runs through;
    - vascular channel
    - venous sinus groove
    - suture

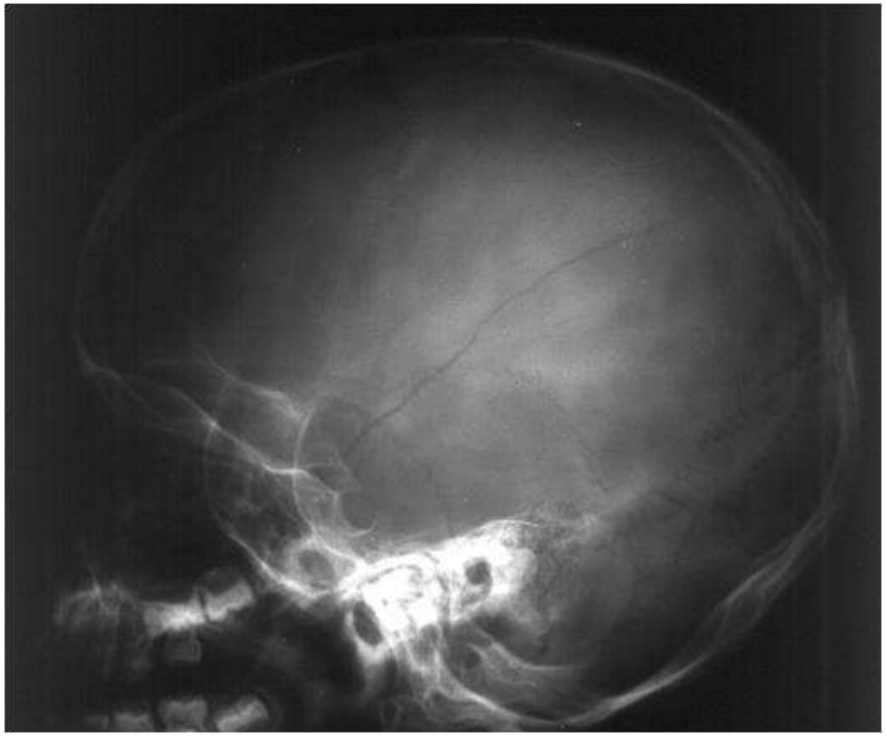

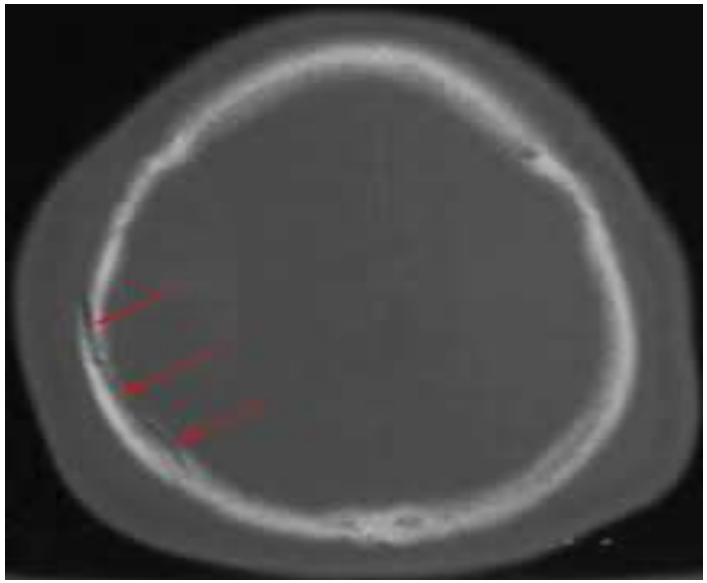

Depressed Skull Fracture

The broken piece of skull bone is pressed towards or embedded in the brain.

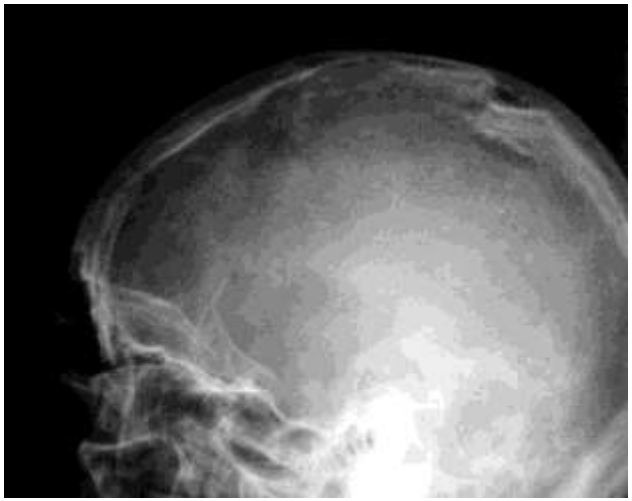

Neurological Deficit.

Dural Tear.

Hematoma .

Infection.

Skull Base Fractures

Anterior cranial fossa

Middle cranial fossa

Posterior cranial fossa

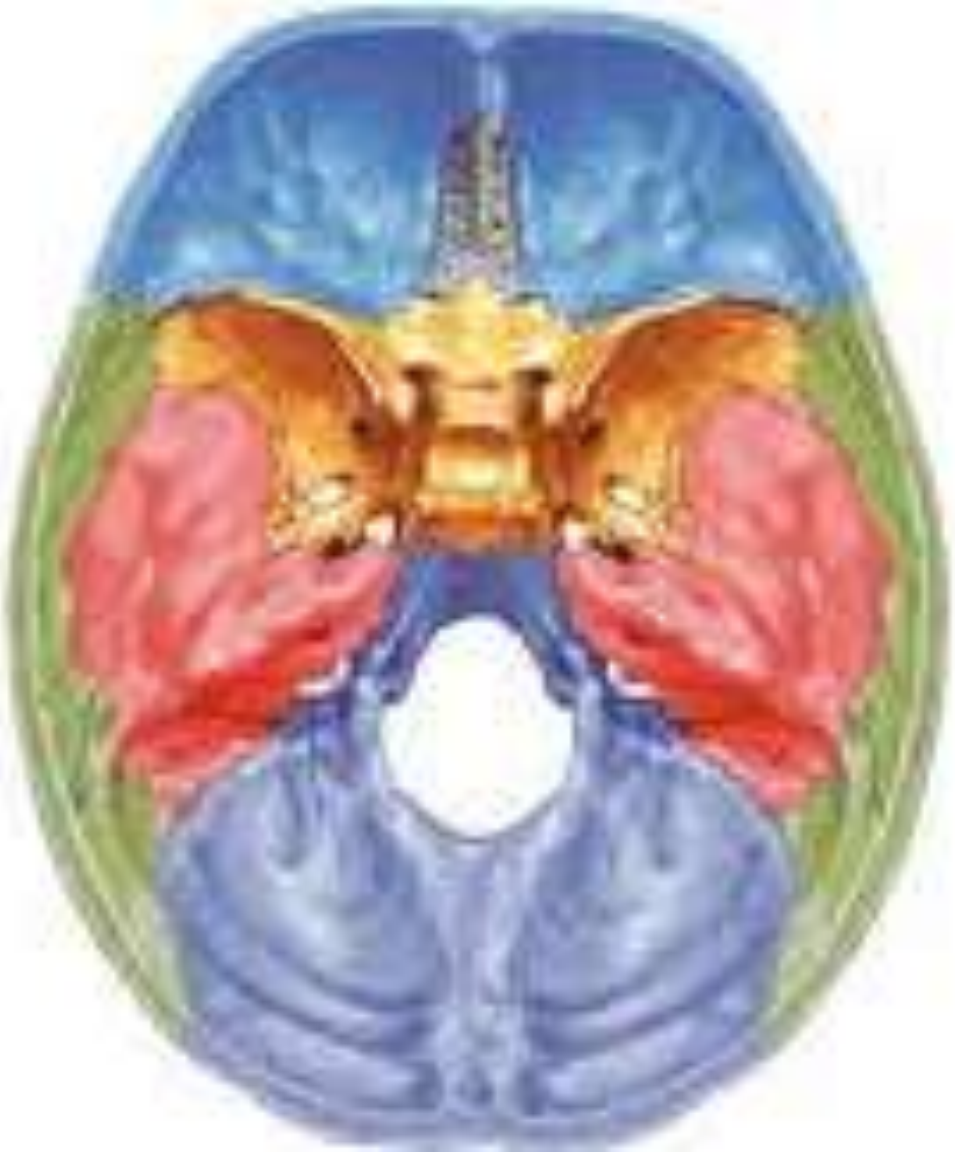

Anterior Skull Base fracture

❖**Diagnosed clinically**.

- CSF rhinorrhea.
- Epistaxis.
- Subconjunctival hemorrhage.
- Periorbital hematomas.
  (raccoon eyes)
- Anosmia.

Middle Skull Base fracture

- CSF otorrhea.
- Hearing loss.
- Battle sign.
- Facial nerve palsy.
- Vertigo &nystagmus.

Posterior Skull Base fracture

- Bruising over occipital area.
- cranial nerve injuries.

The double ring sign
(Halo Sign)

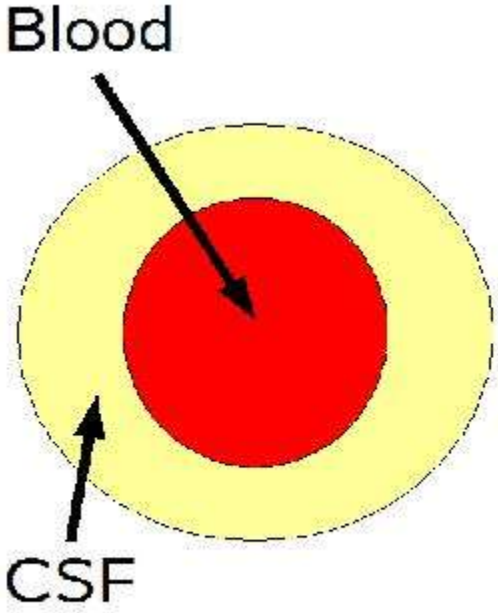

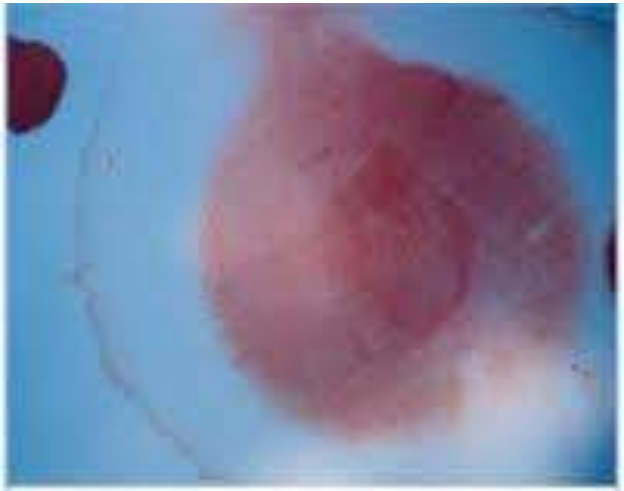

Brain Injury

An insult to the brain, caused by an external physical force.

Injuries

- Blunt
- Penetrating

PATHOPHYSIOLOGY

- **Primary Brain Injury :**

  - occurs at the time of impact

  - Mechanical damage is irreversible

  - Permanent mechanical cellular disruption

  - Microvascular injury.

includes - cerebral contusions

- diffuse axonal injuries (DAI)

- cerebral lacerations

- **Secondary Brain Injury**

  Occurs at some time after the moment of impact

  Preventable—>>>improved outcome.

Causes of secondary brain injury

- Hypoxia: $PO_2 < 8$ kPa
- Hypotension: systolic blood pressure (SBP) < 90 mmHg
- Raised intracranial pressure (ICP): ICP > 20 mmHg
- Low cerebral perfusion pressure (CPP): CPP < 65 mmHg
- Pyrexia
- Seizures
- Metabolic disturbance

TYPES OF BRAIN INJURIES

DIFFUSE

- Concussion
- Diffuse Axonal Injury

FOCAL

- Contusion
- Lacerations
- Epidural hge
- Subdural hge
- Subarachnoid hge
- Intracerebral hge

CONCUSSION

"Any trauma-induced alteration in mental status"

Temporary & brief interruption of neurological function without structural damage.

Cause

- shearing / stretching of white matter fibres at the time of impact ==>> temporary neuronal dysfunction.

CONCUSSION

- Brief confusion, disorientation.
- Headache.
- Dizziness.
- Amnesia.
- Return of consciousness moments or minutes after impact (within 30 minutes).

- **CT/MRI → Normal**

Post-concussive syndrome

Timing: 2 weeks to 2 months

c /o

- Persistent headache
- fatigue
- Personality changes
- Short attention span
- Decreased short-term memory
- sleep disturbances
- depression, personality disorders

Diffuse Axonal Injury

Severe widespread injury to axons in the cerebral hemispheres, corpus collosum, and brain stem.

Diffuse Axonal Injury

Clinical signs:

- ↓ LOC immediately
- ↑ ICP
- Decerebration or decortication.
- Cognitive impairment, spasticity .
- 90% pts with severe DAI will be vegetative.
- CT → usually normal

Epidural hematoma

- Collection of blood between dura and bones of the skull.
- Skull # present 75-95% of cases.
- Source ; Arterial (MMA) , Venous.

Pathophysiology;

- fracture of temporal bone ruptures branches of the middle meningeal artery.

- stripping of dura from the calvarium --->> severe headache.

Brief LOC, headache, drowsiness, dizziness , nausea, vomitting.

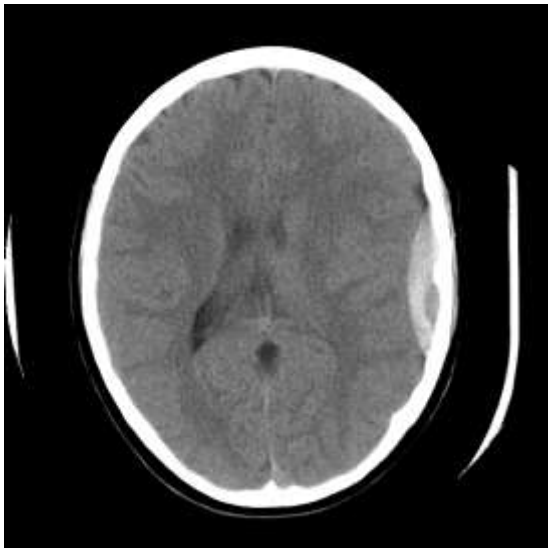

lucid interval

Rapid clinical deterioration

- ❑hematoma expansion
- ❑elevated intracranial pressure
- ❑brain herniation

Acute subdural Hematoma

- Accumulates in space between dura and arachnoid
- Source; - Disrupted cortical vessels (A,V)
  - Brain laceration produces hematoma
- Signs within 48 hours of the injury.
- Associated with major trauma (Shearing Forces)
- Mortality rate as high as 40% in some series

CT scan

- ✓ Hyperdense
- ✓ Concave
- ✓ Spreading across brain

- ✓ Midline shift disproportionate to size of lesion

Chronic subdural Hemorrhage

- Elderly on anti coagulant or anti platelet.
- History: minor head injury in weeks or months prior to presentation
- Small bridging veins tear ➔ small, clinically silent hematoma ➔ increases in size ➔ mass effect.
- **c/f:** headache, cognitive impairment, focal neurological deficit and seizures.

Chronic Subdural Hematoma

→

Subarachnoid Hemorrhage

- defined as blood within the CSF.

- Trauma is most common cause (tears of small subarachnoid vessels), followed by Aneurysms.

- Rarely aneurysmal hemorrhage immediately preceedes trauma.

- Most can be managed conservatively

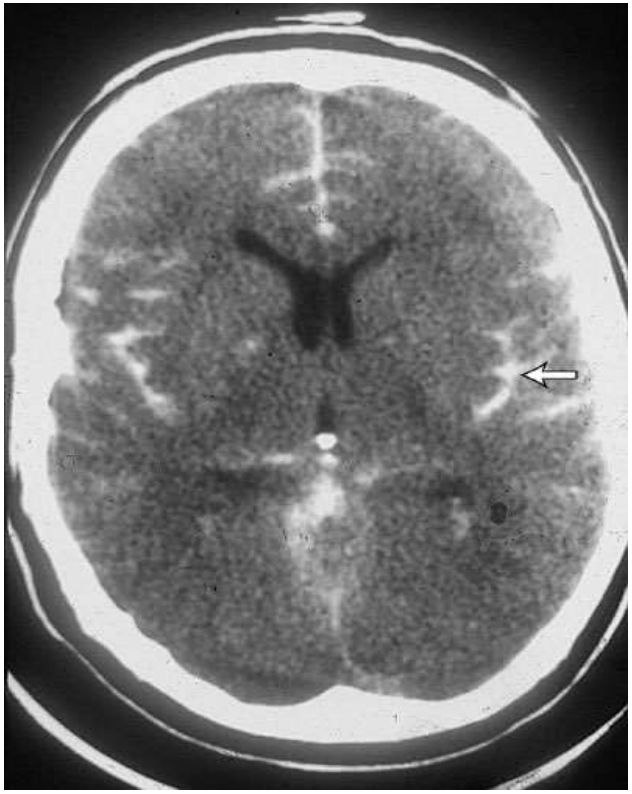

Cerebral contusions

- Coup and counter coup injuries.
- Most commonly affecting inf frontal fossa and temporal lobes
- CT appears heterogeneous with mixed areas of high and low density.
- Observation, Rarely require immediate surgery

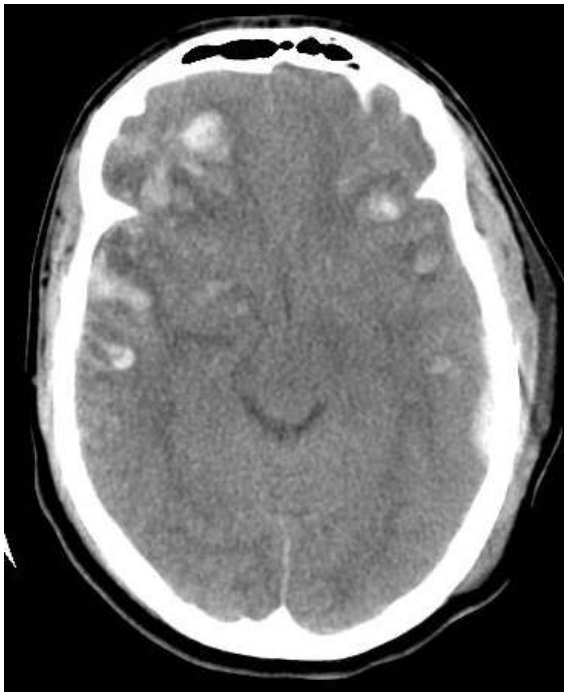

Intracerebral Hematoma

Bleeding directly into the brain tissue.

Two main types:

1) ***Intra-parencymal***
2) ***Intra-ventricular***

Causes

Trauma
Hypertension (70-80%)
Ruptured AVM
Coagulopathy

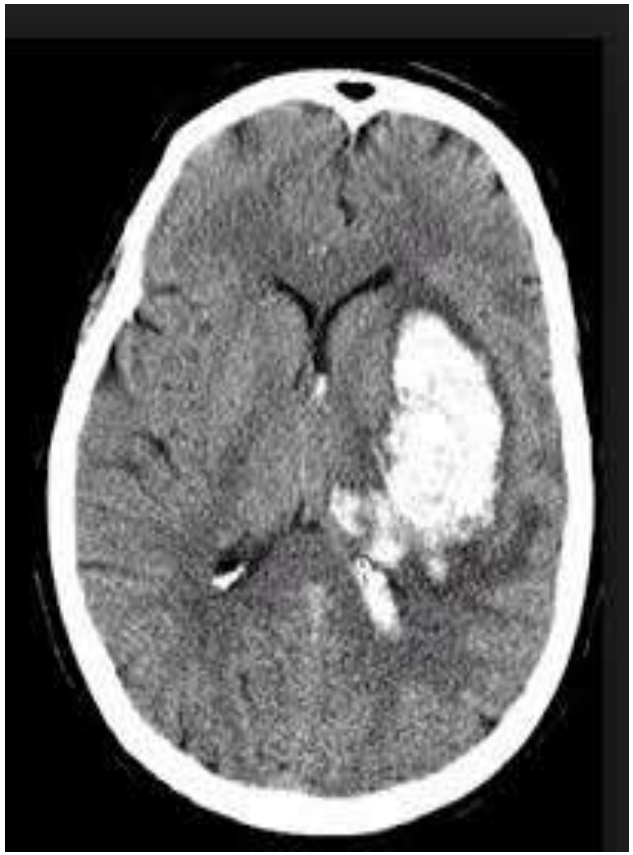

Intra-parencymal hge

Intra-ventricular hge

Clinical presentation

- Progressive severe headache (several minutes).
- Nausea and vomiting.
- Focal neurological deficits .
- Decreased level of consciousness.
- Brain herniation.

Thank You!