



Tishk
International University

Faculty of Applied Science
Medical Analyses Department

1st Grade

Assist Prof. Dr. Sangar M. AHMED

MS Zahra

E. mail: sangar.ahmed@tiu.edu.iq

@Dr.Sangarjaff

Respiratory System

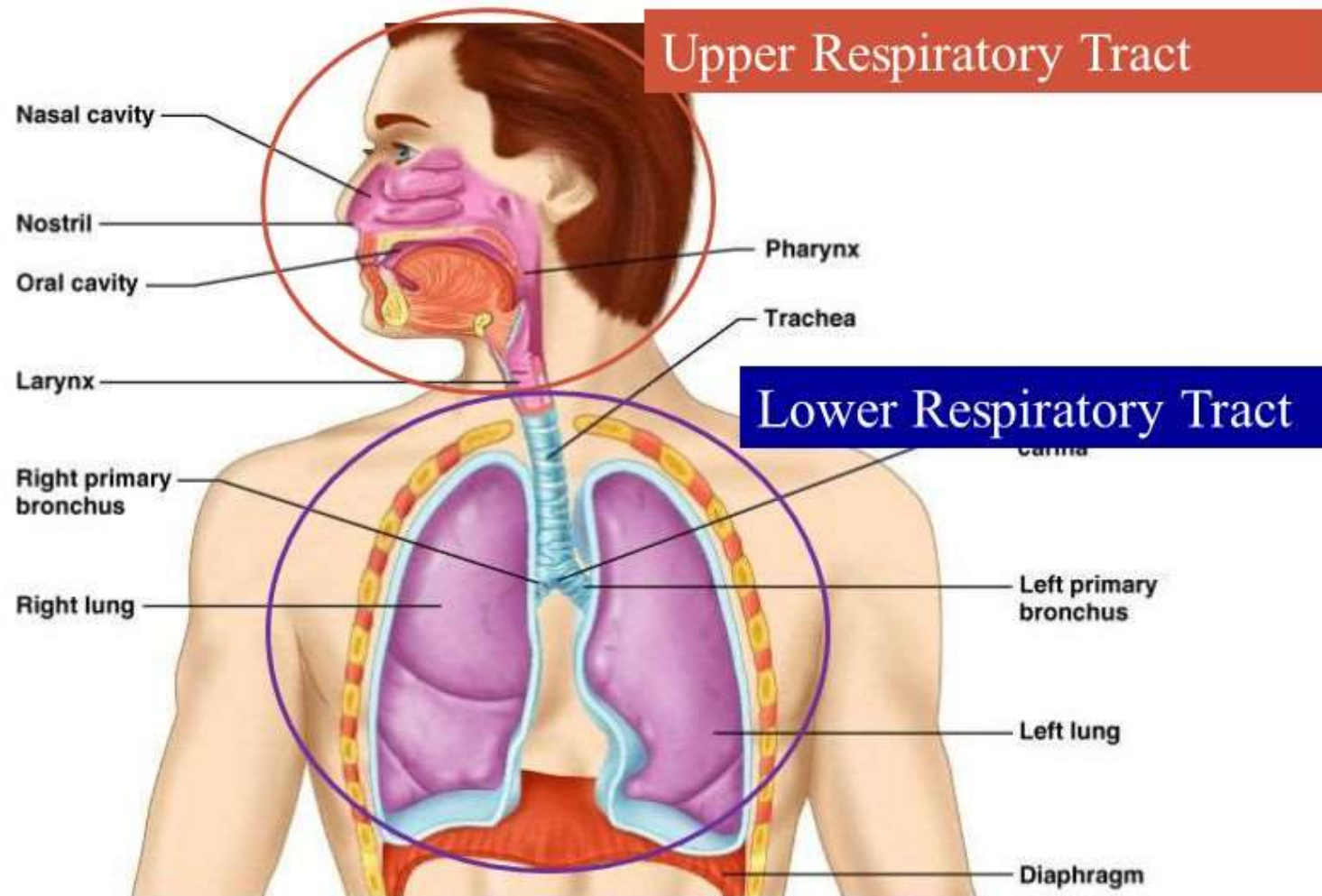
Lab.

Human Anatomy Lab

Spring Semester

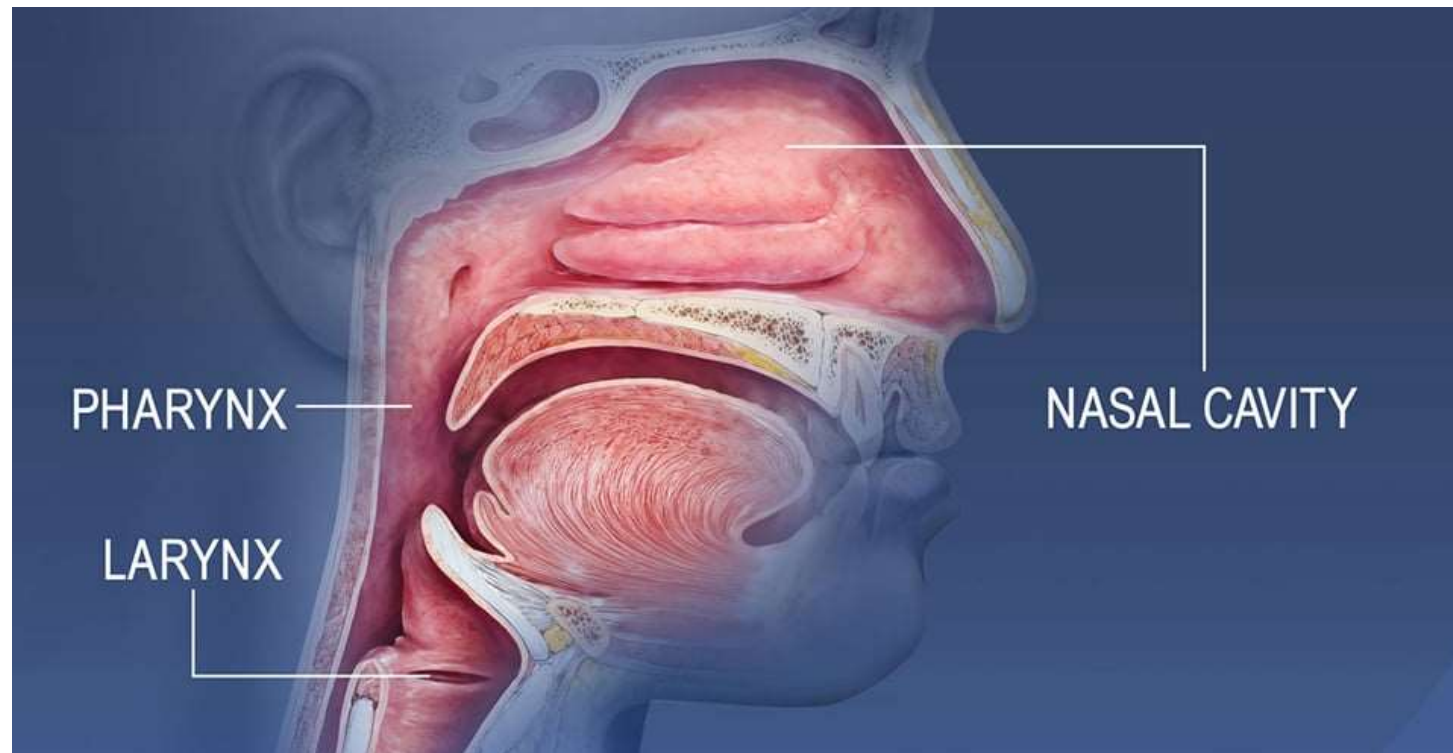
Week No. 2

Divisions of the Respiratory System

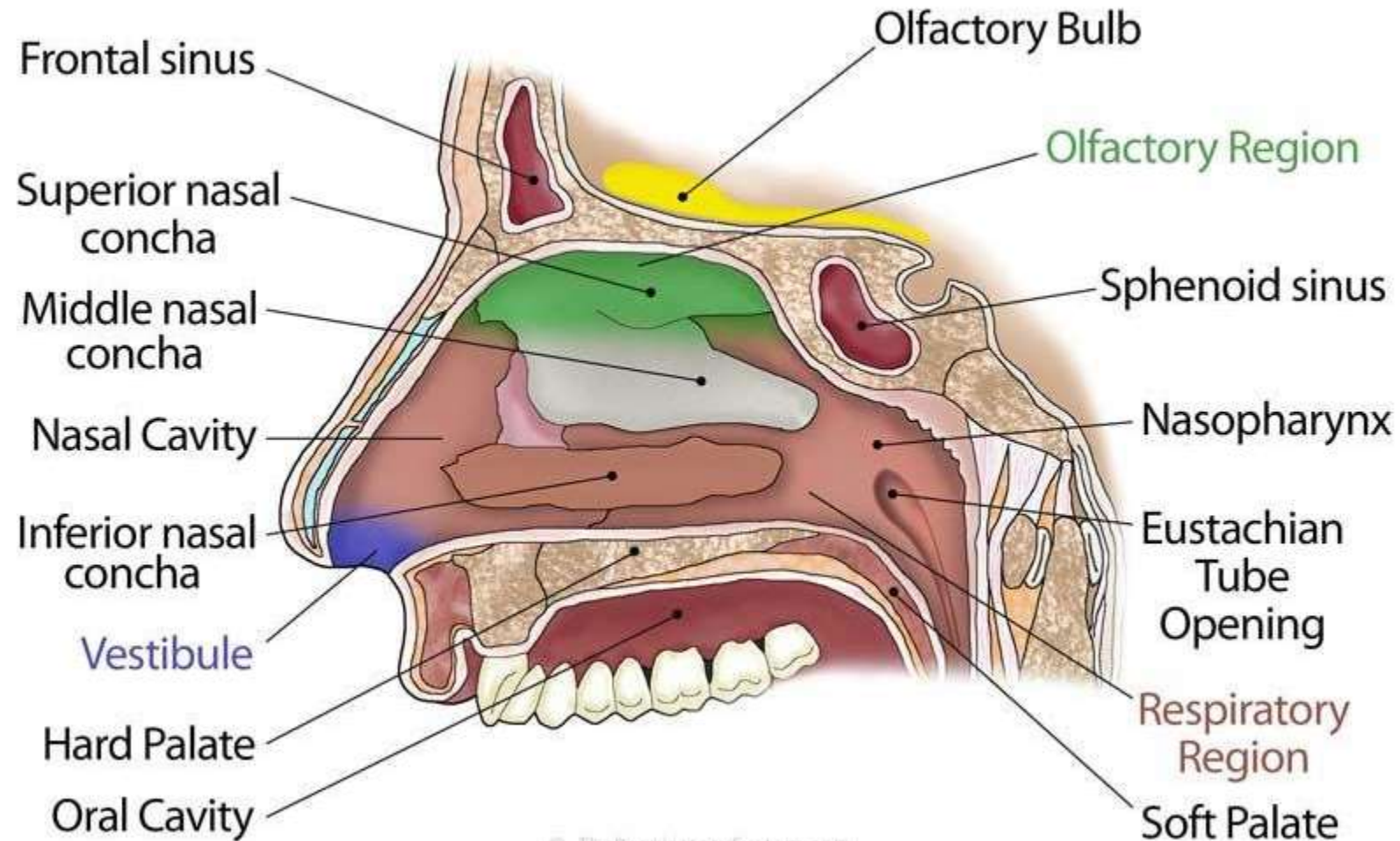


Upper Respiratory tract

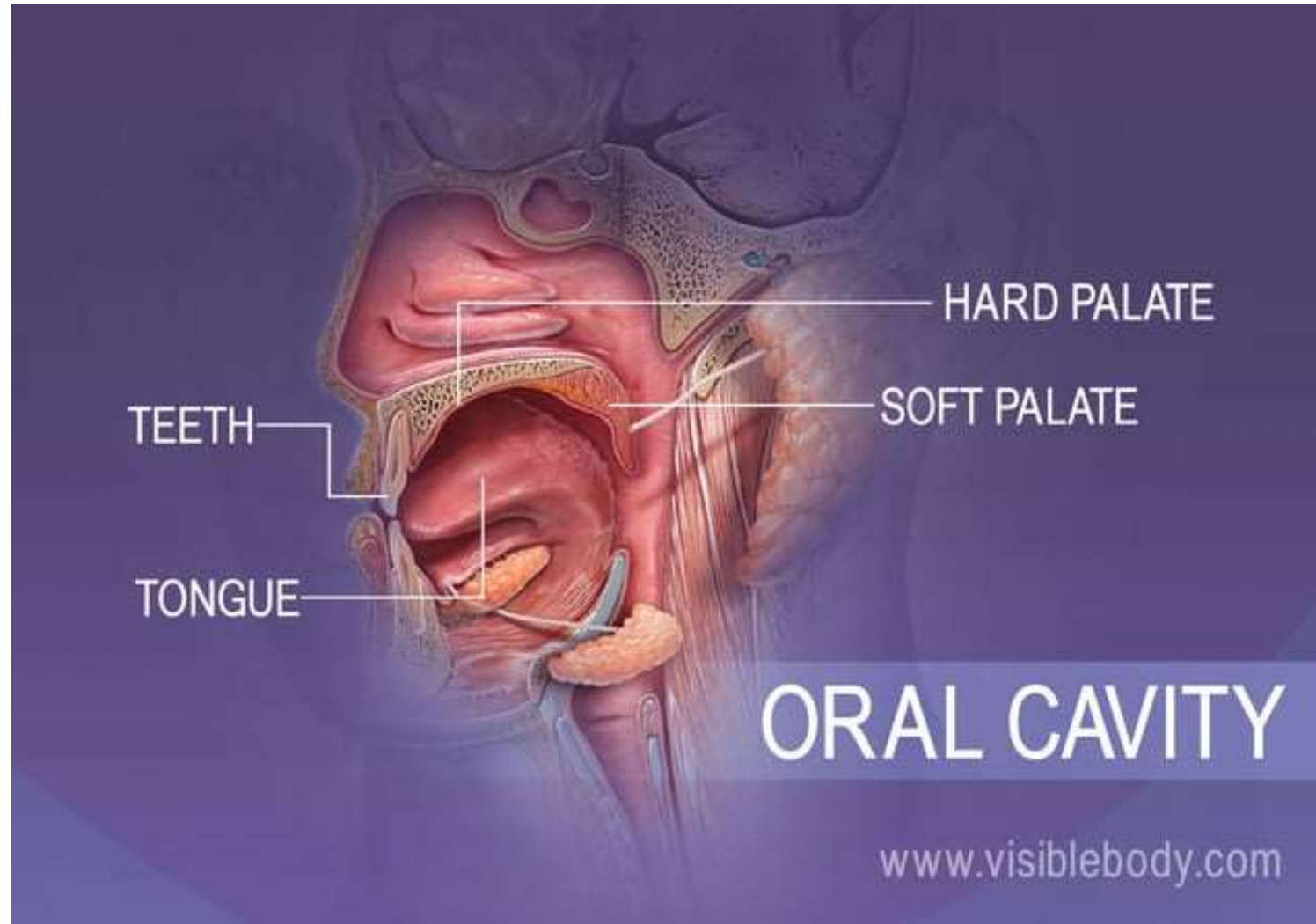The upper respiratory tract refers to the parts of the respiratory system that lie outside the thorax, more specifically above the cricoid cartilage and vocal cords



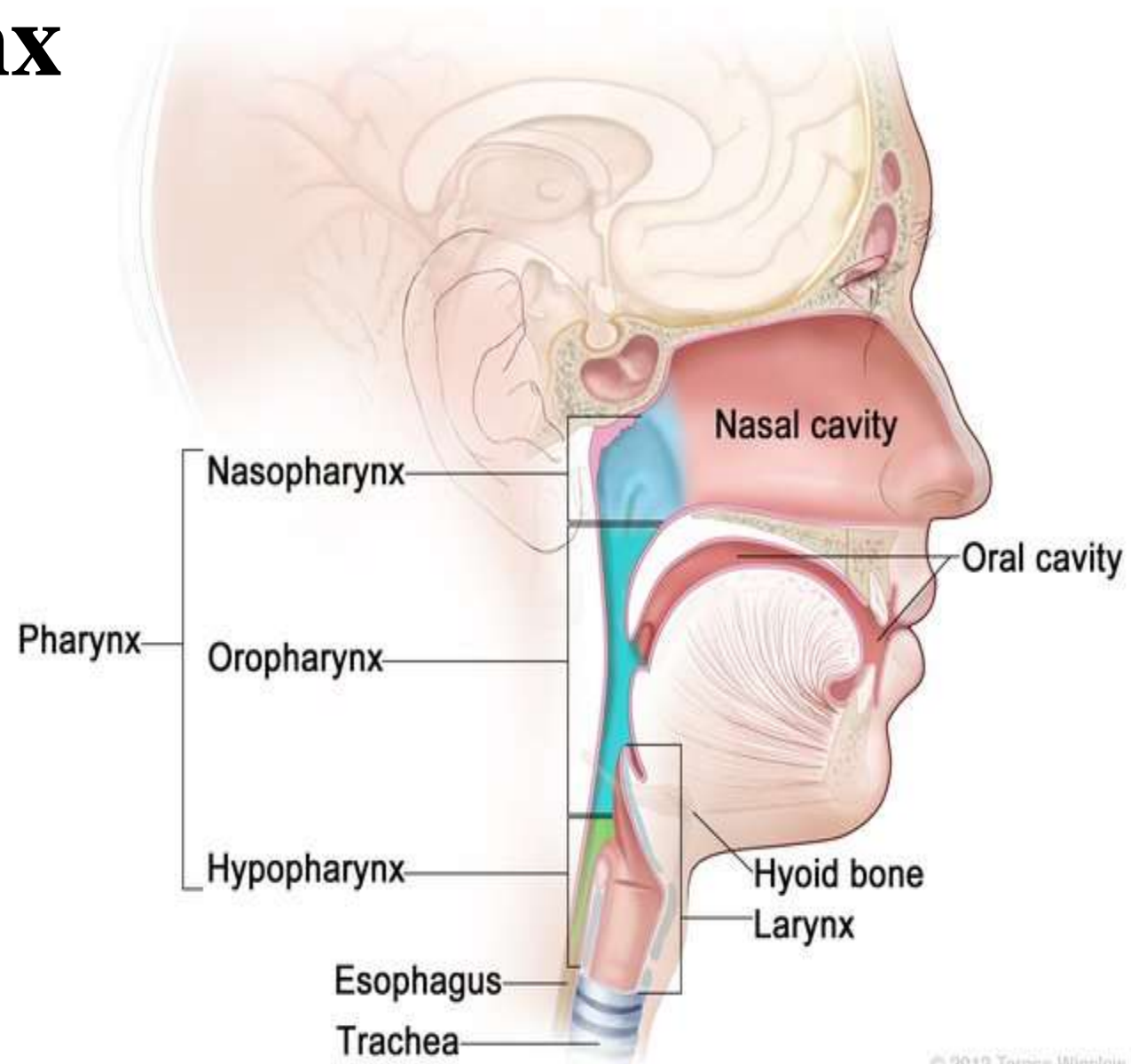
Nasal Cavity



Mouth (Oral Cavity)

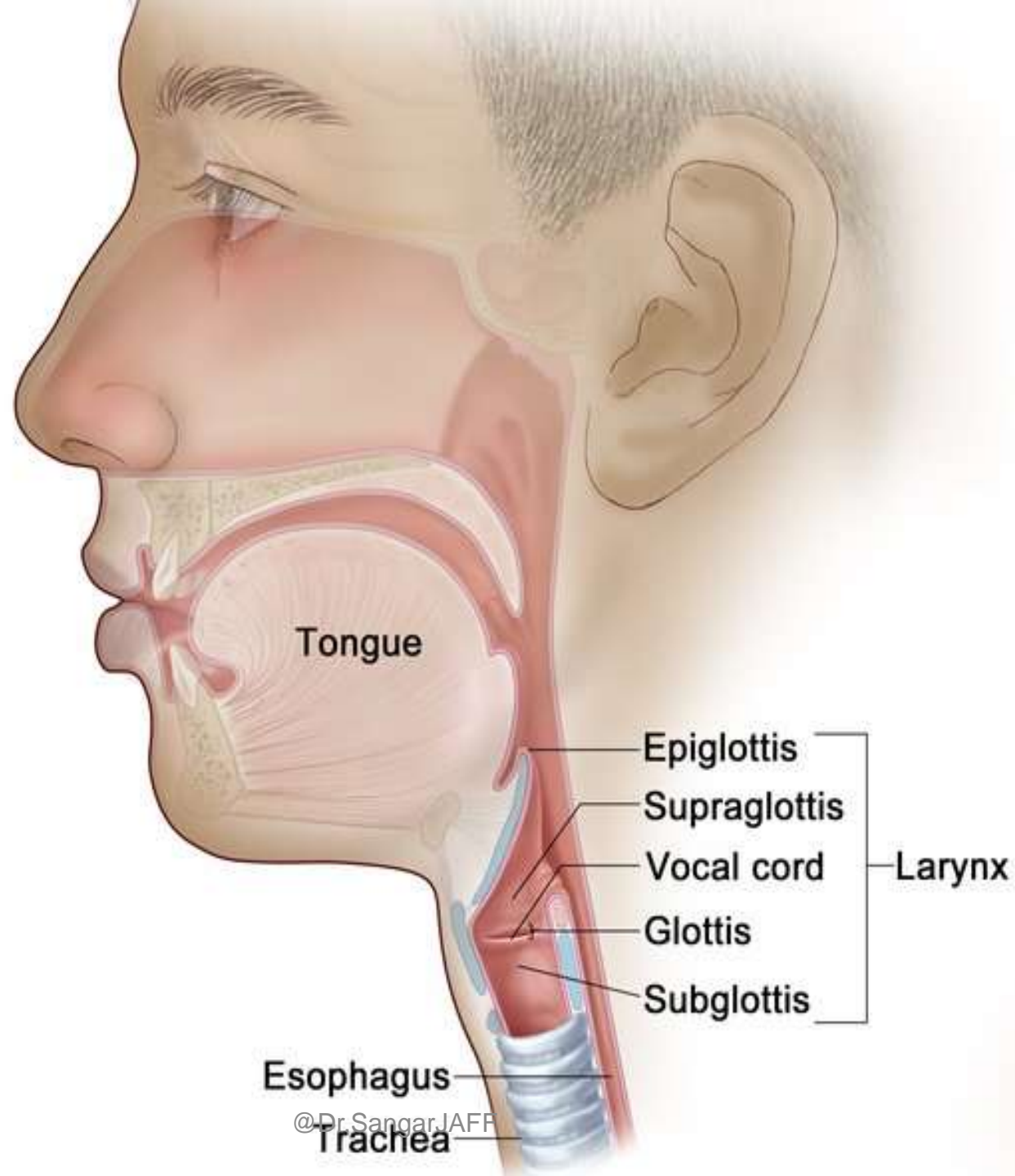


Pharynx

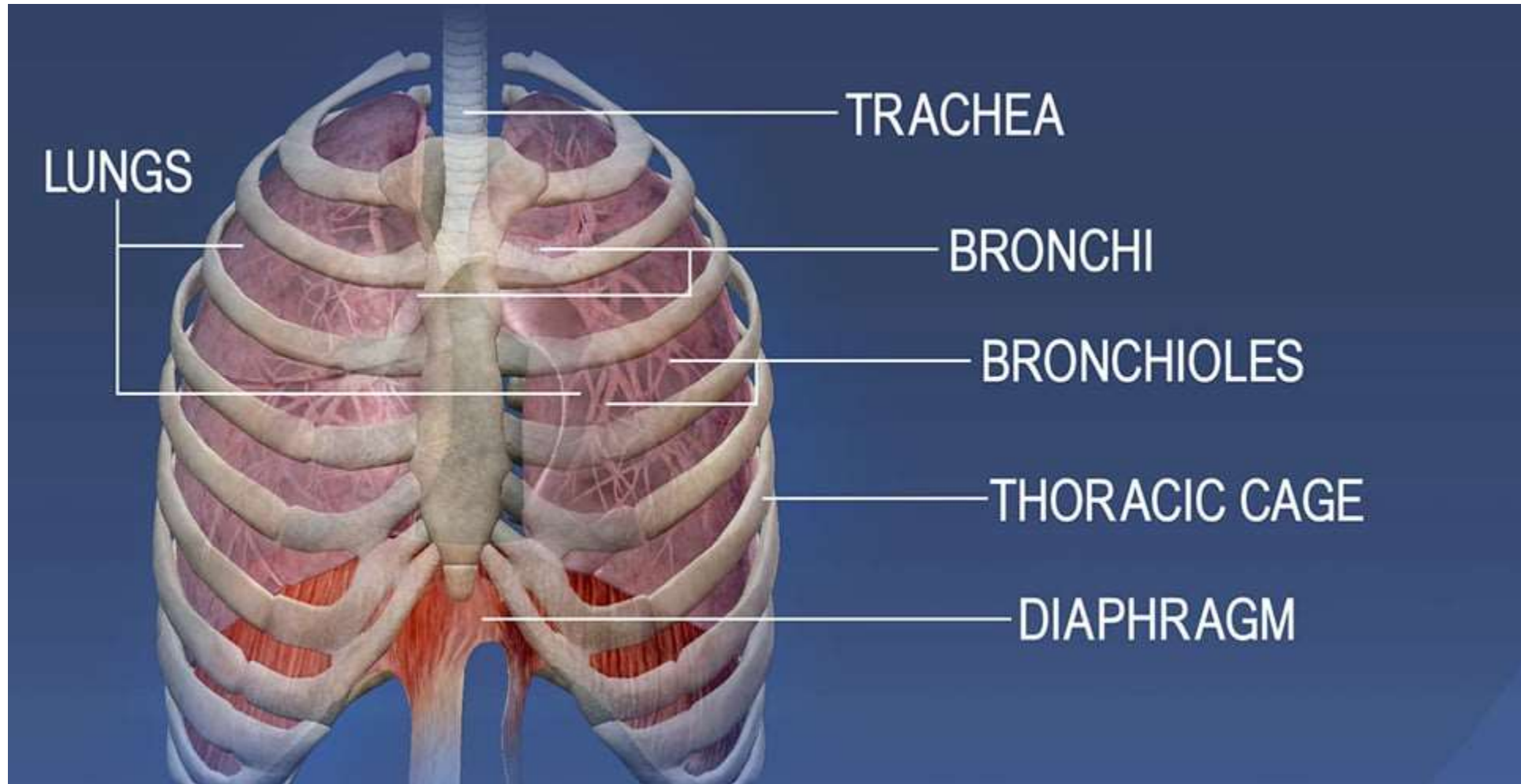


© 2012 Terese Winslow LLC
U.S. Govt. has certain rights

Larynx

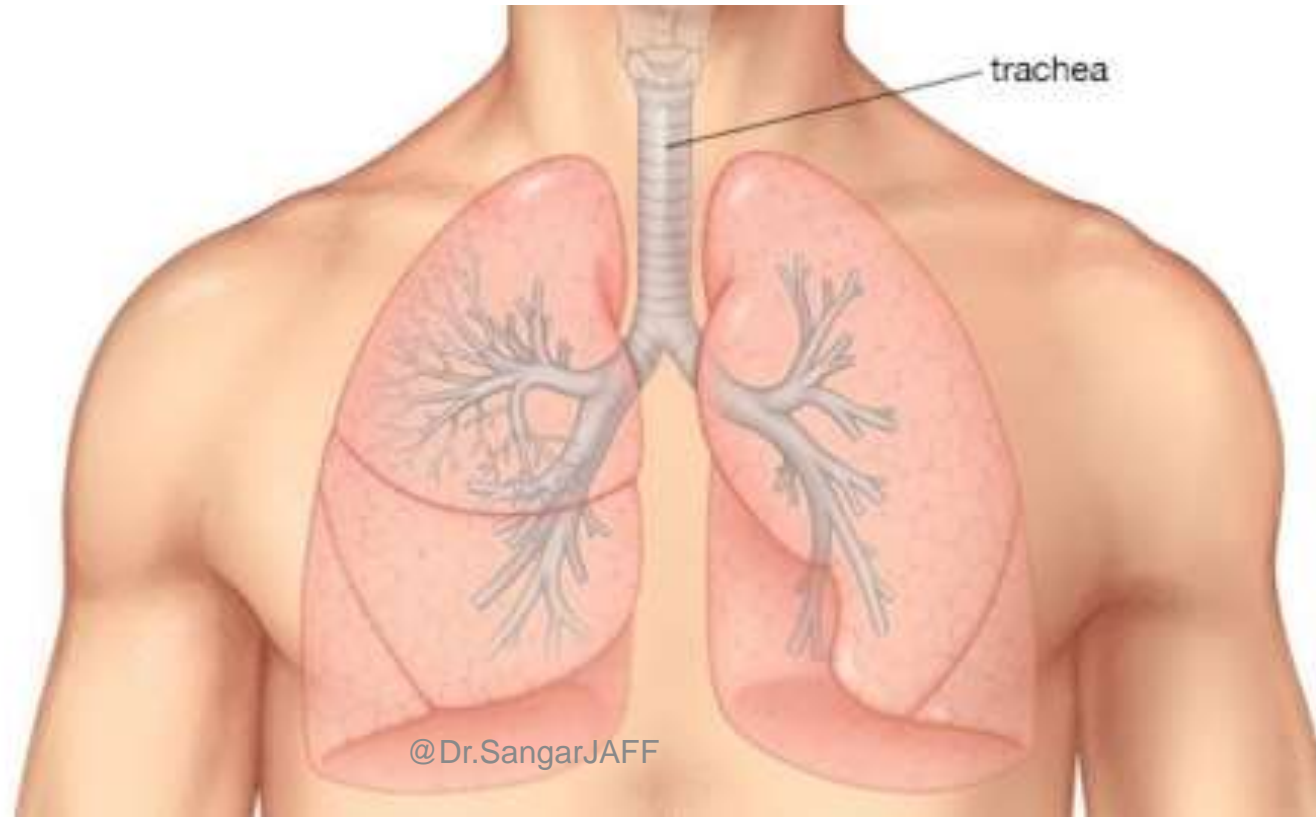


Lower Respiratory tract

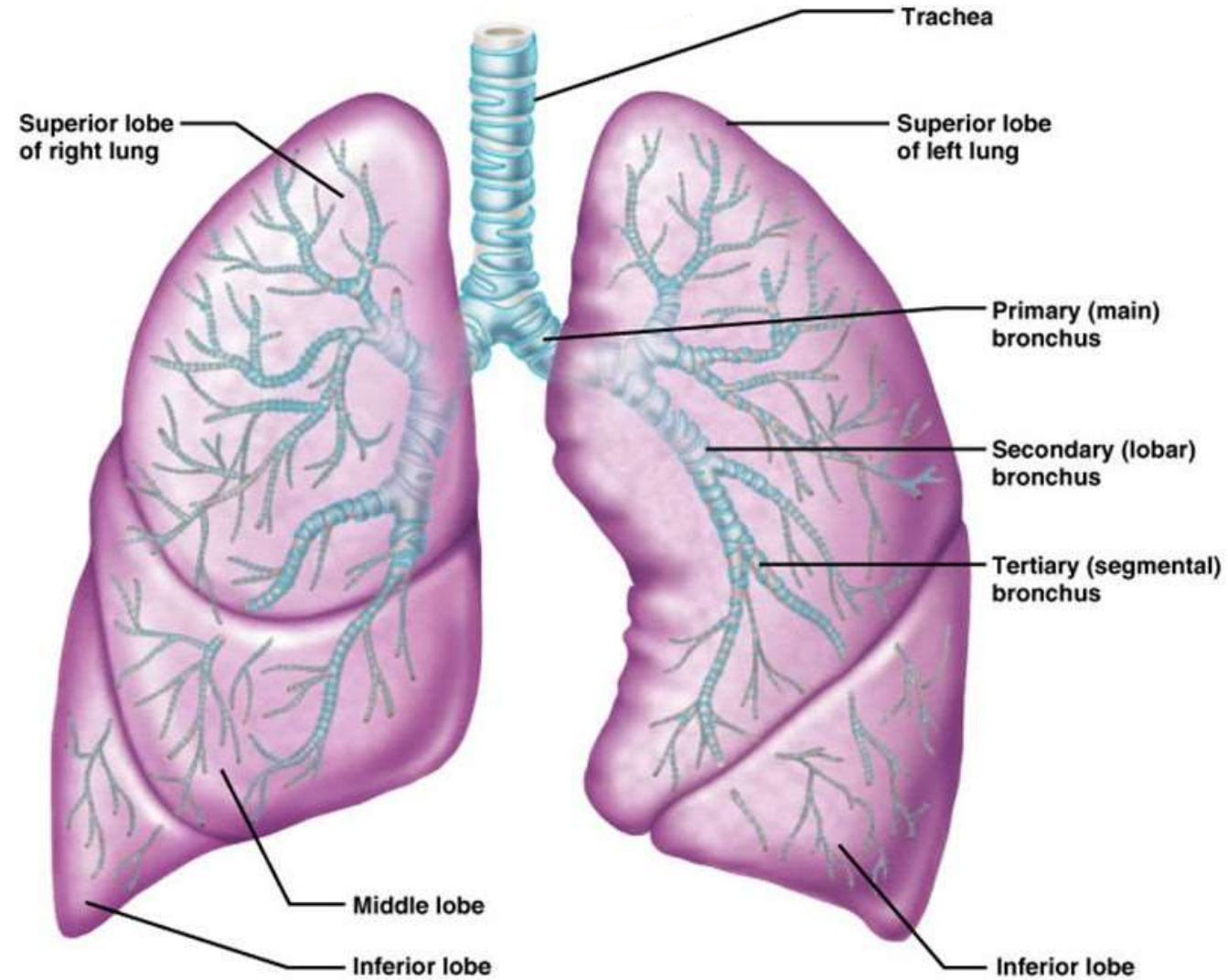


Trachea

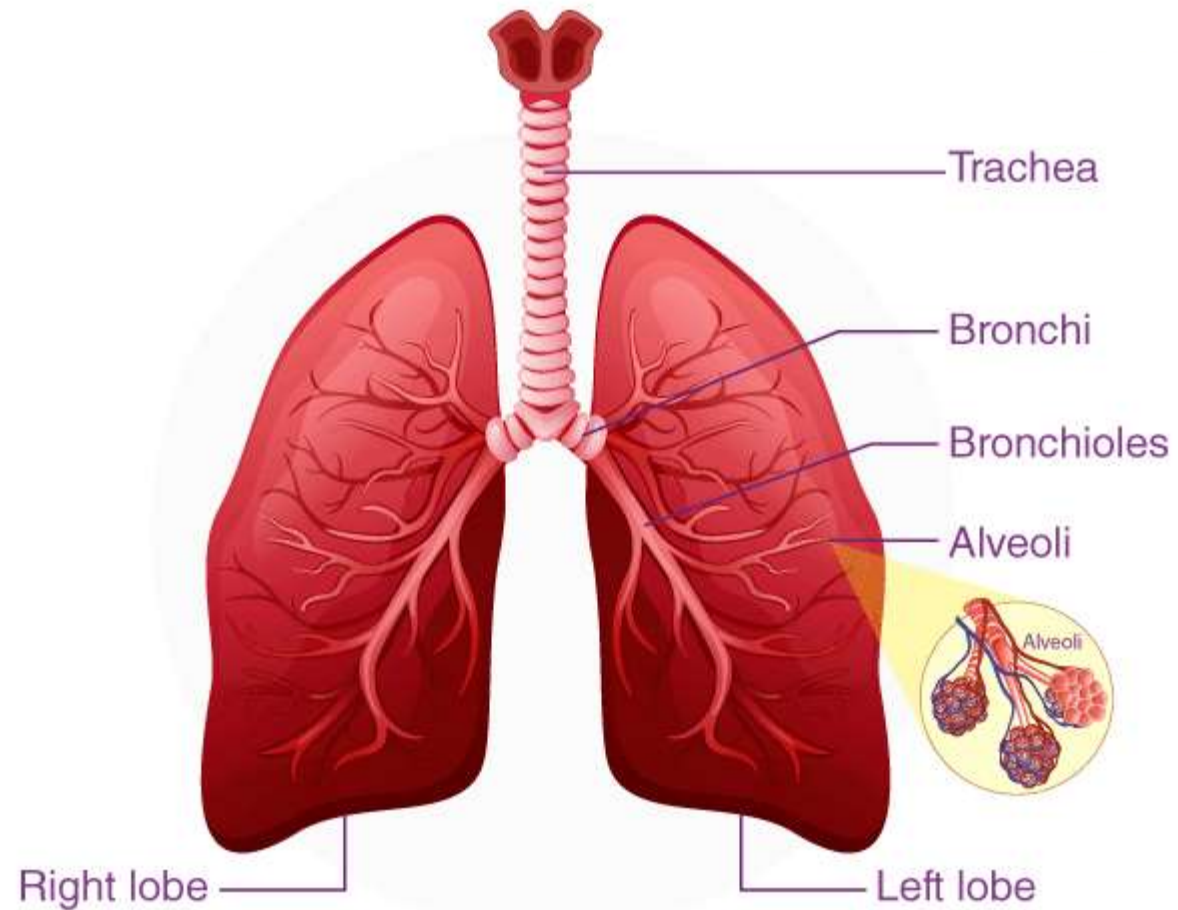
Trachea: Located just below the larynx, the trachea is the main airway to the lungs.



Lungs



Bronchi



Diaphragm

