



**Tishk**  
International University

**Faculty of Applied Science**  
**Medical Analyses Department**

**1<sup>st</sup> Grade**

**Assist Prof. Dr. Sangar M. AHMED**

**MS Zahra**

E. mail: [sangar.ahmed@tiu.edu.iq](mailto:sangar.ahmed@tiu.edu.iq)

@Dr.Sangarjaff

# Digestive System

## Lab.

**Human Anatomy Lab**

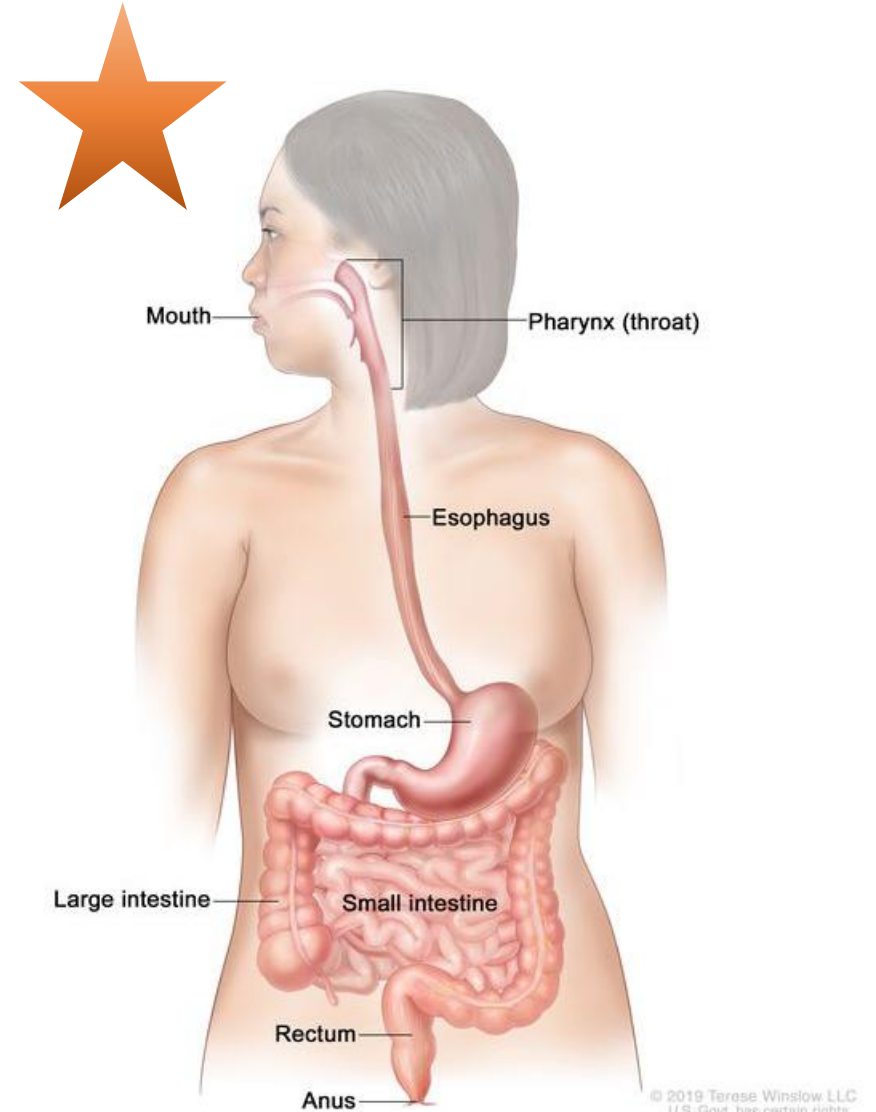
**Spring Semester**

**Week No. 3**

# The digestive system composed of two main groups of organs

## A. Alimentary Canal (nutrition)

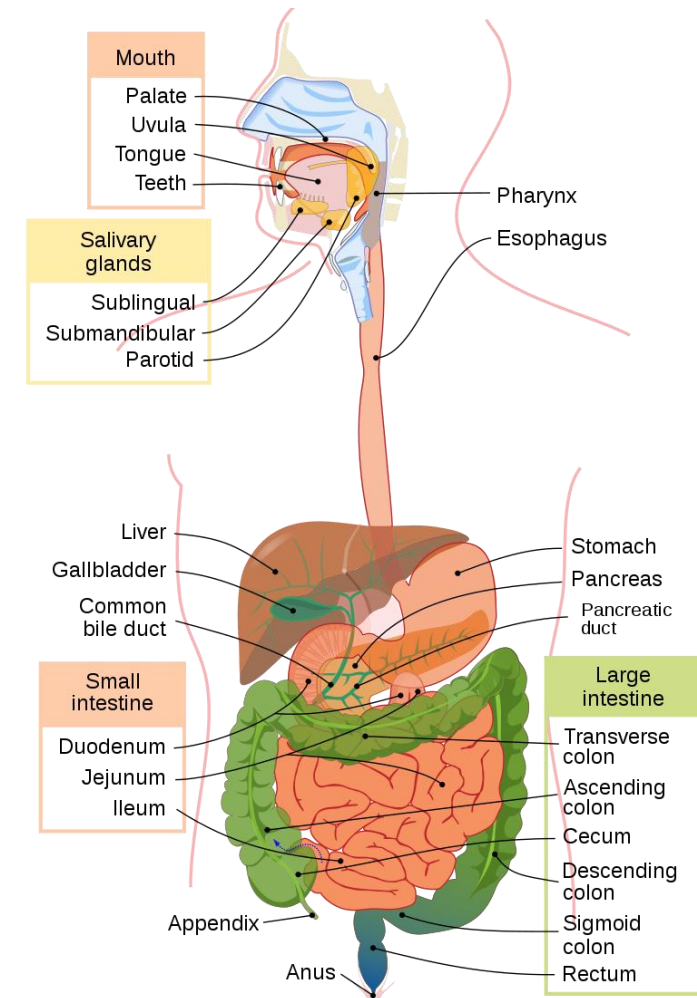
1. Mouth
2. Pharynx
3. Esophagus
4. Stomach
5. Small bowel
6. Large bowel



# The digestive system composed of two mains groups of organs

## B. Accessory Digestive Organs

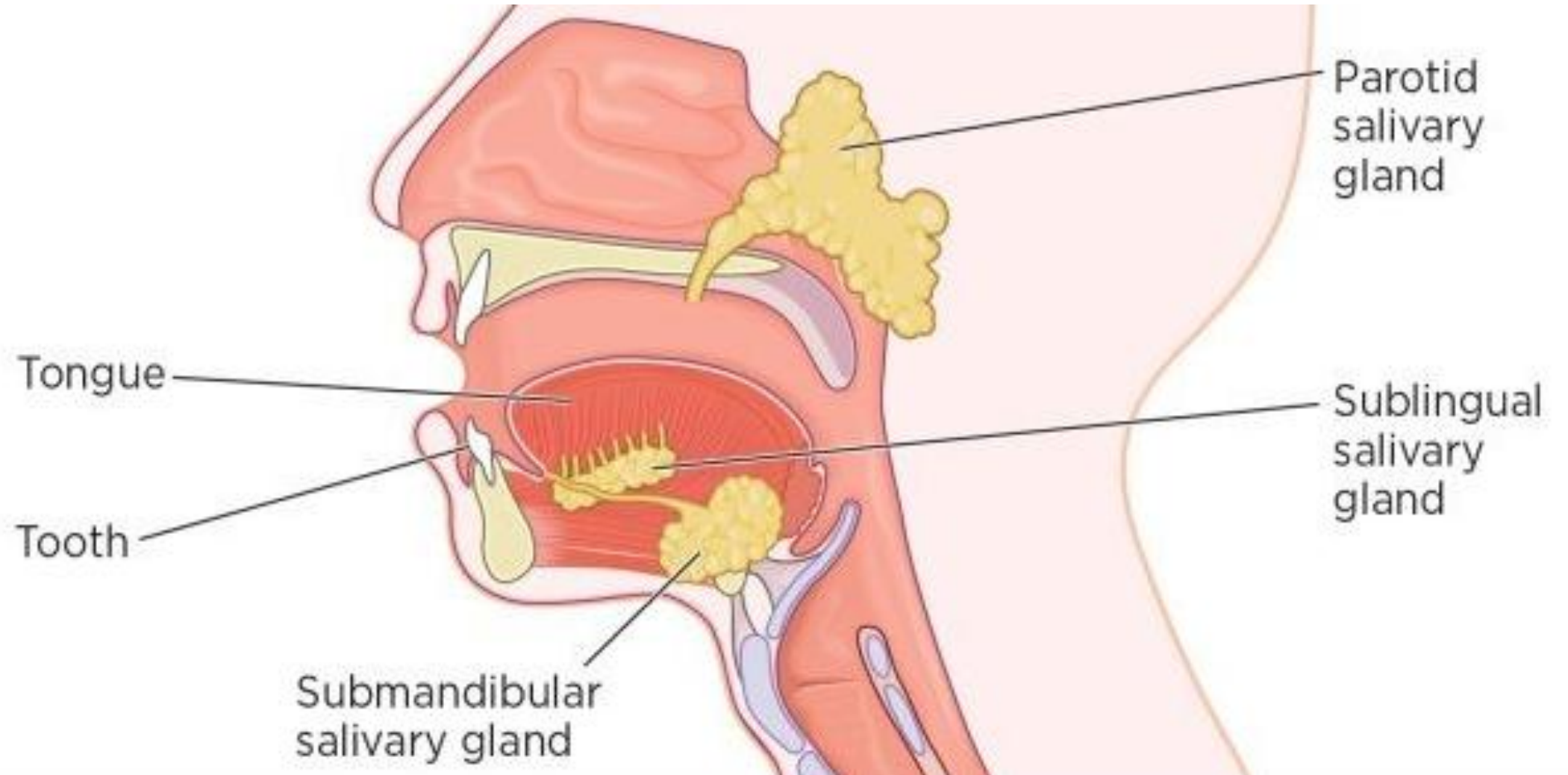
1. Teeth
2. Tongue
3. Gall bladder
4. Salivary glands
5. Liver
6. pancreas



# Functions of the digestive System

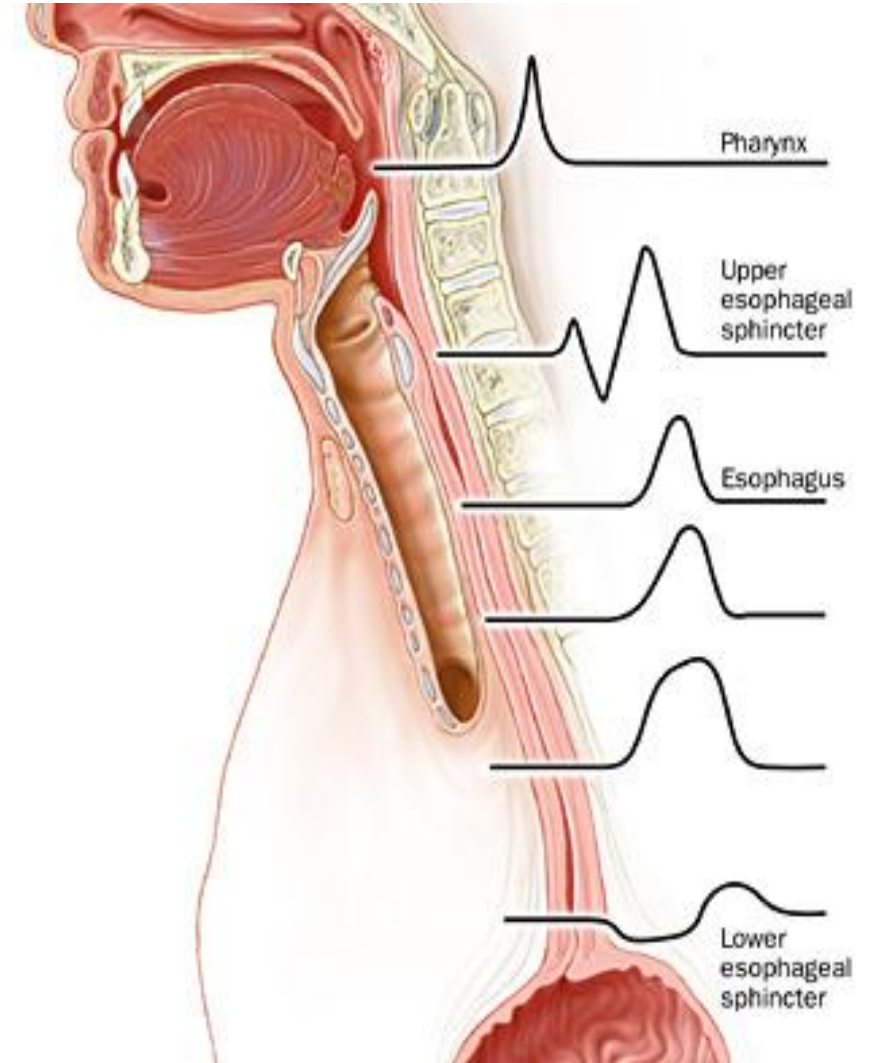
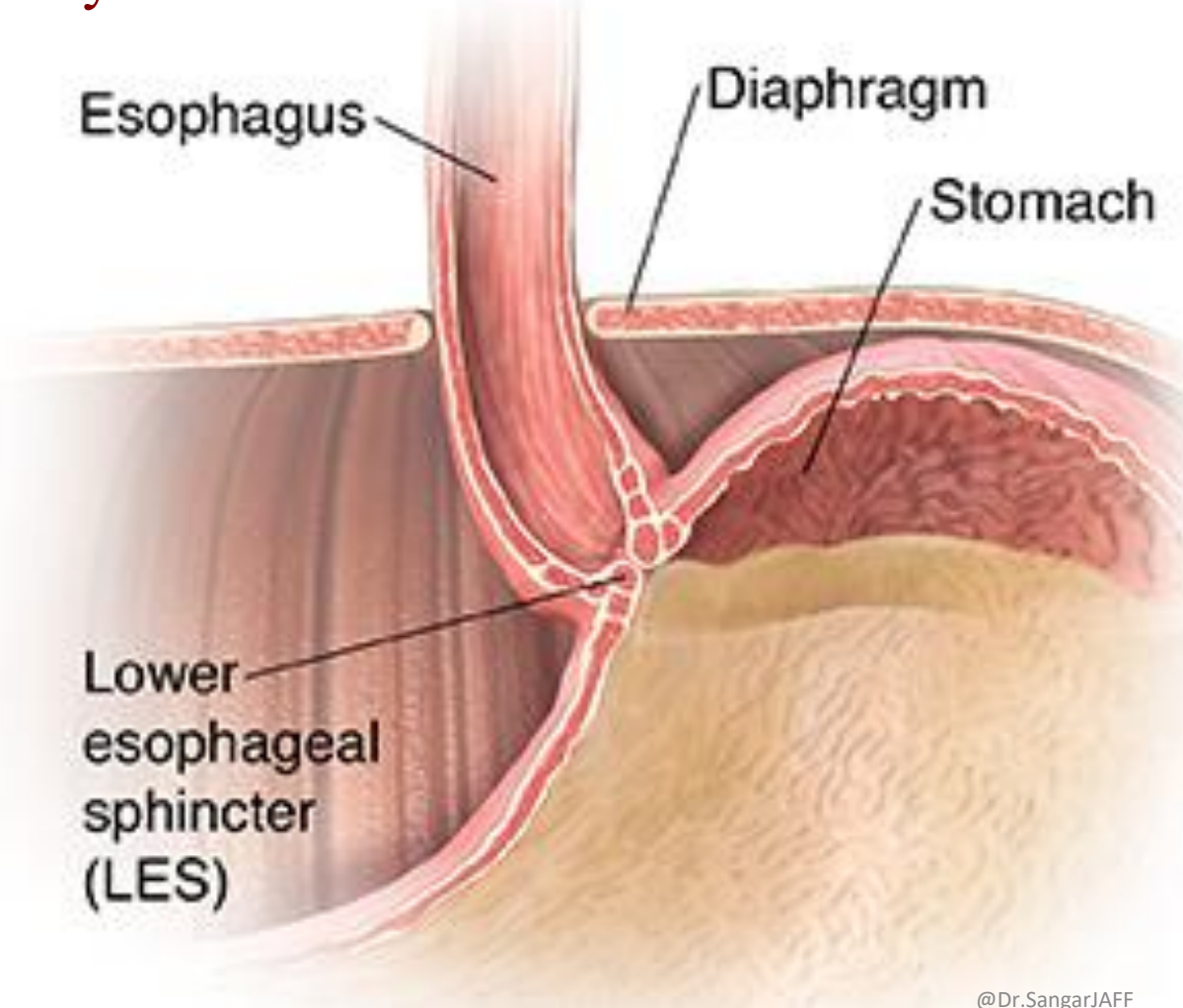
1. **Digestion** of food into nutrients
2. **Absorption** of nutrients into the bloodstream
3. **Elimination** of solid wastes.

# Mouth

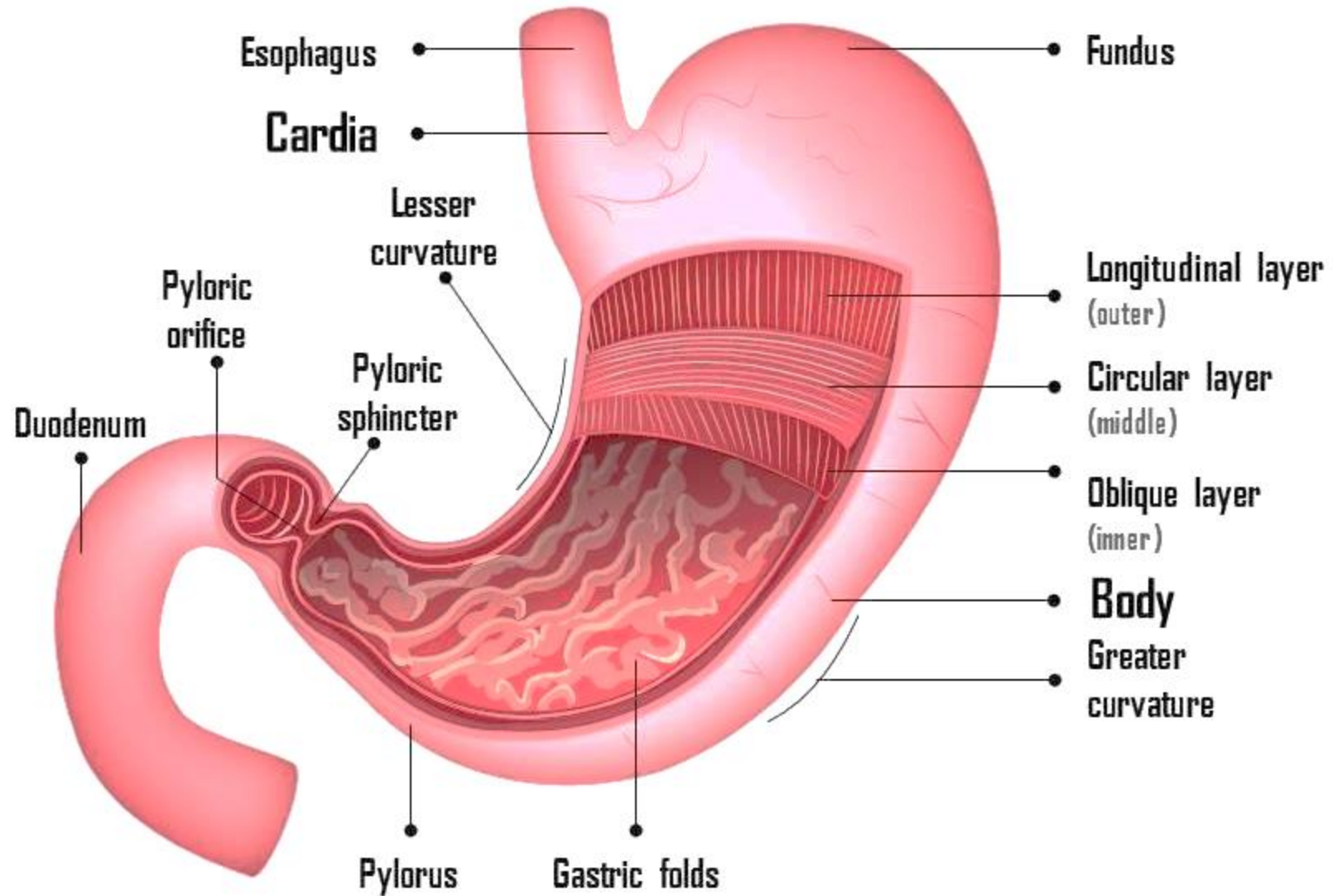


# Esophagus

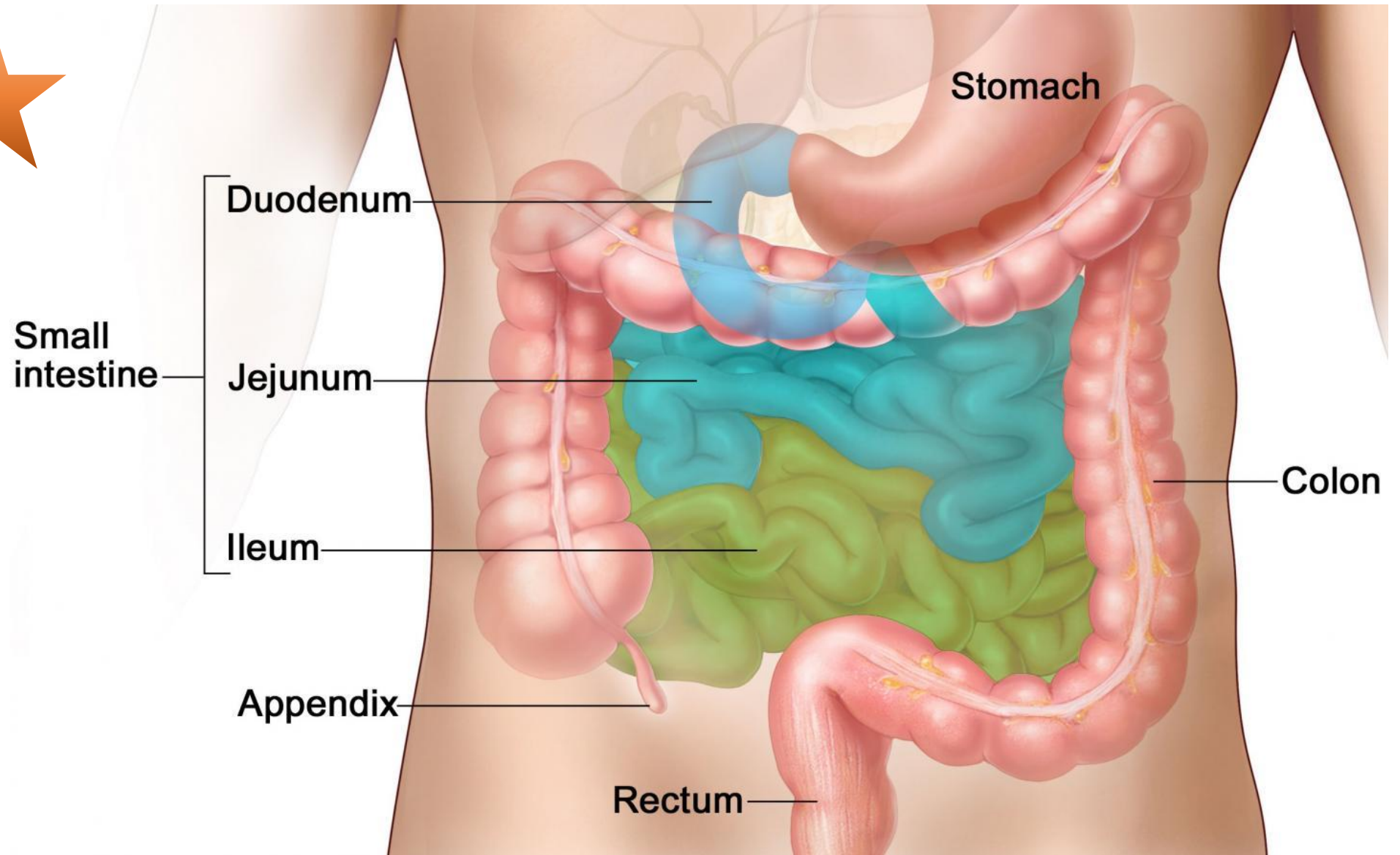
The primary function of the esophagus is to carry food and liquid from the mouth to your stomach



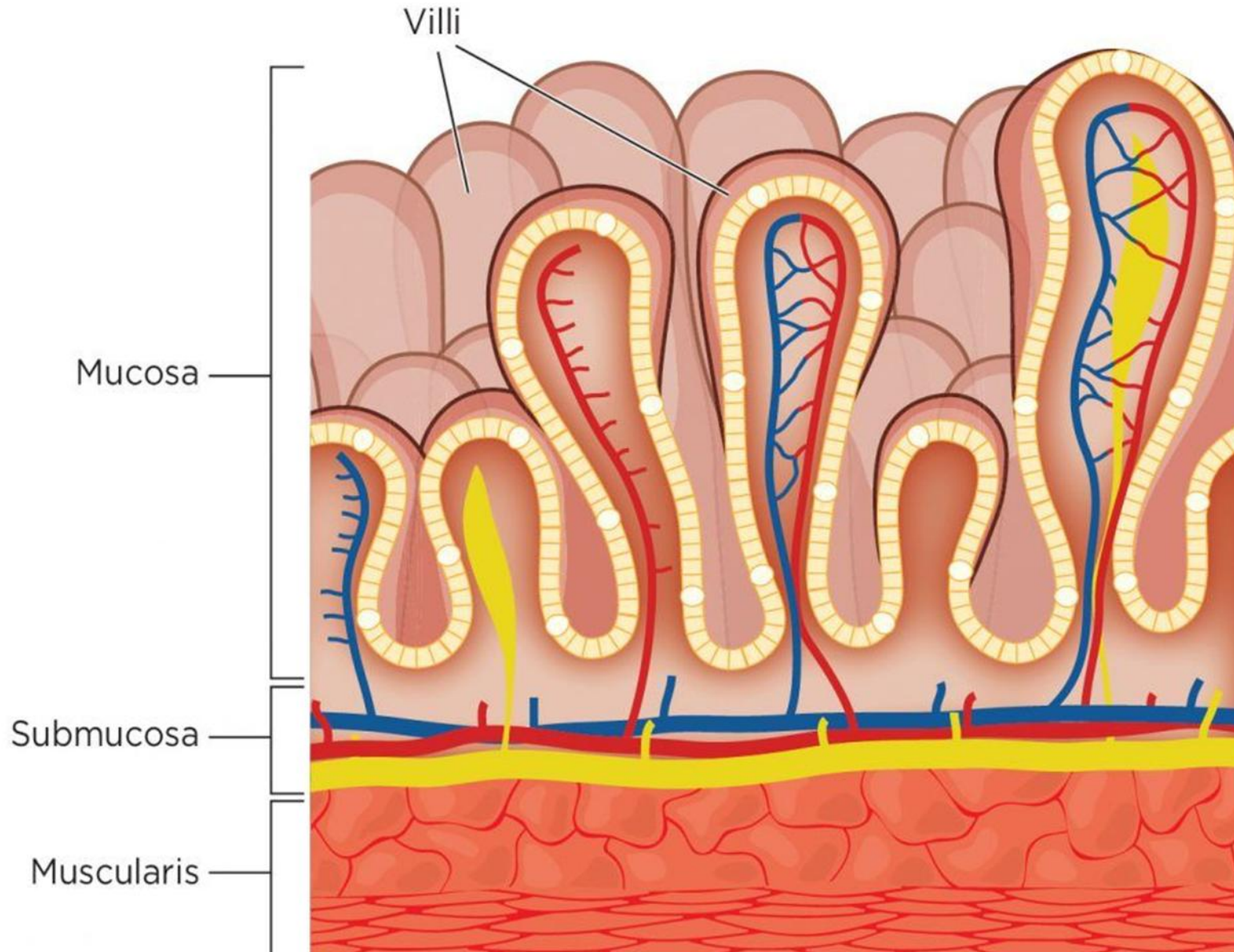
# Stomach



# Small intestine

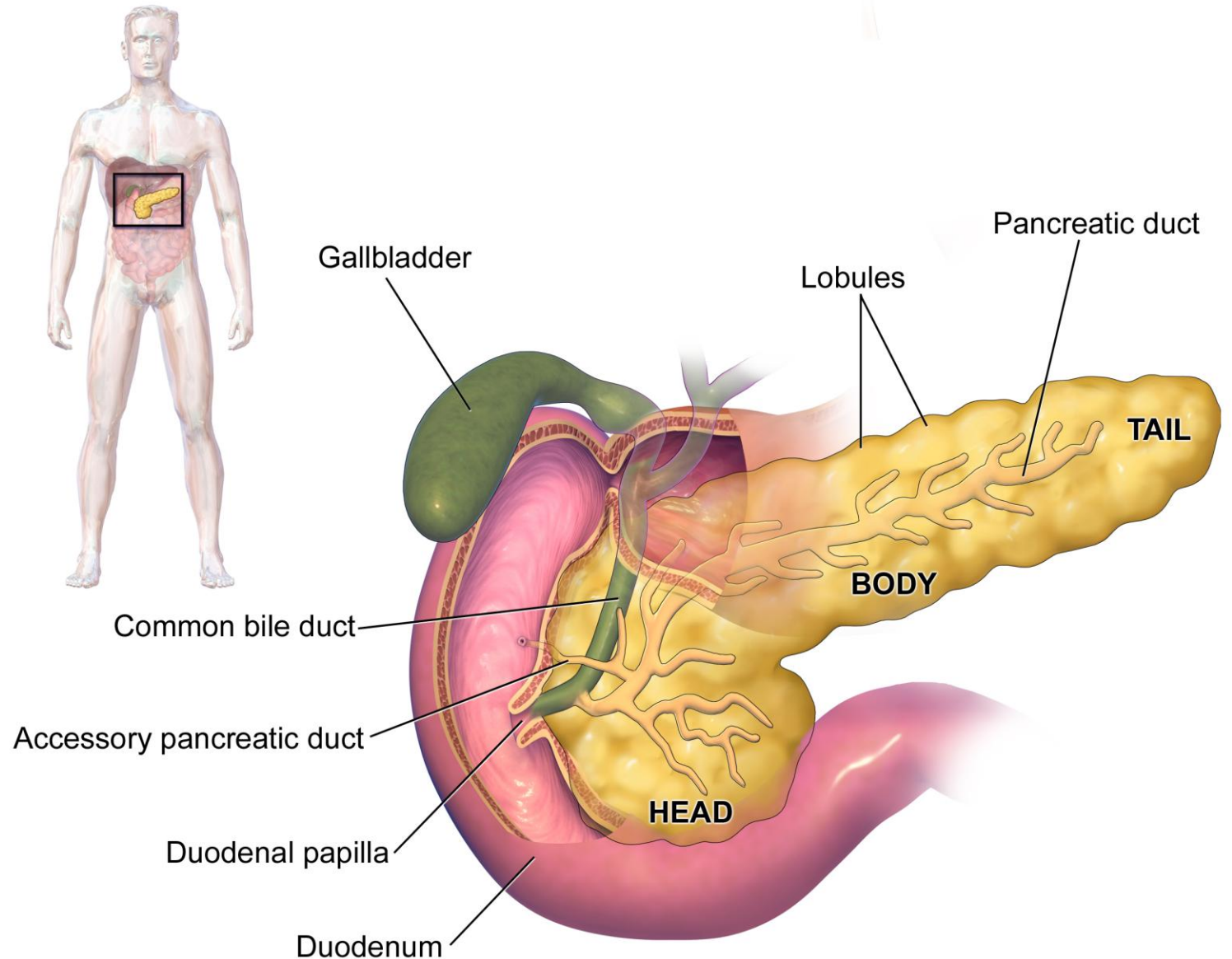


# Small intestine

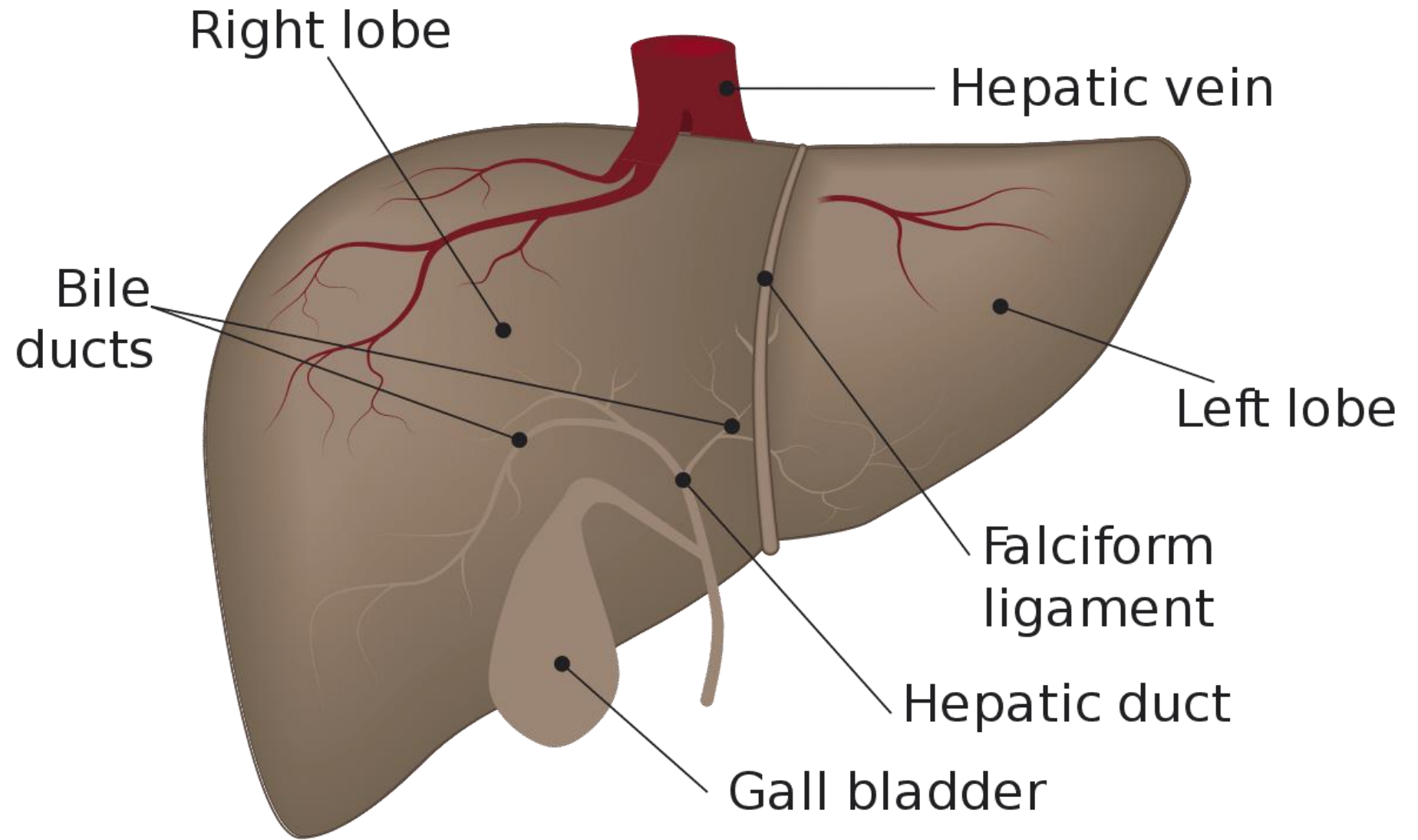


# Pancreas

The pancreas is an elongated, tapered organ located across the back of the belly, behind the stomach.



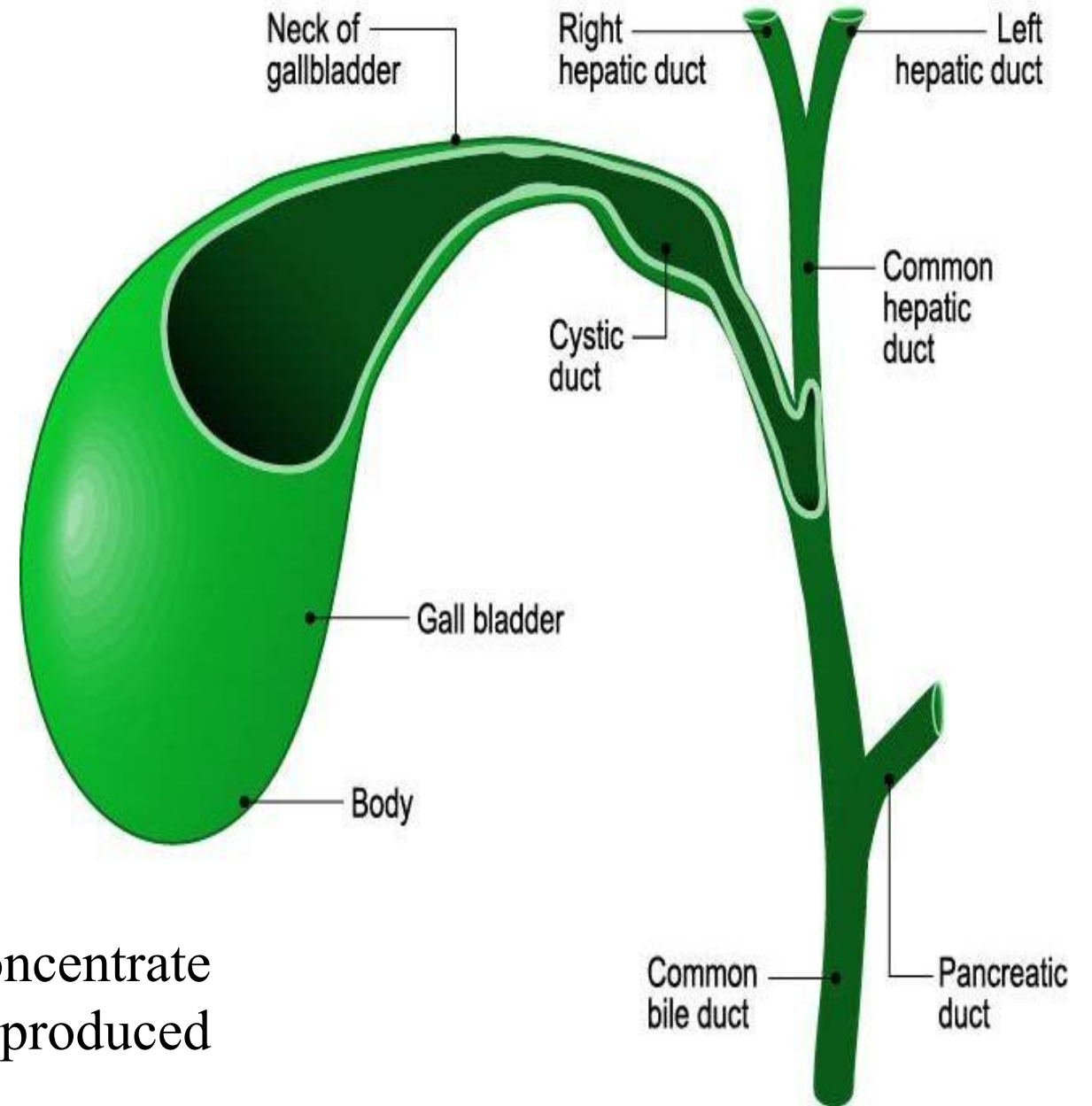
# Liver



# Gallbladder

The gallbladder is a pear-shaped, hollow structure located under the liver and on the right side of the abdomen.

Its primary function is to store and concentrate bile, a yellow-brown digestive enzyme produced by the liver.



# Colon

The ascending colon travels up the right side of the abdomen. The transverse colon runs across the abdomen. The descending colon travels down the left abdomen. The sigmoid colon is a short curving of the colon, just before the rectum

