

Tishk International University
Faculty of Applied Science
Nutrition and Dietetics Department



Anatomical Terms

Human Anatomy / 1st Lab
1st Grade / Spring Semester

Instructor: Adam Jalal Mohammed

Email: adam.jalal@tiu.edu.iq



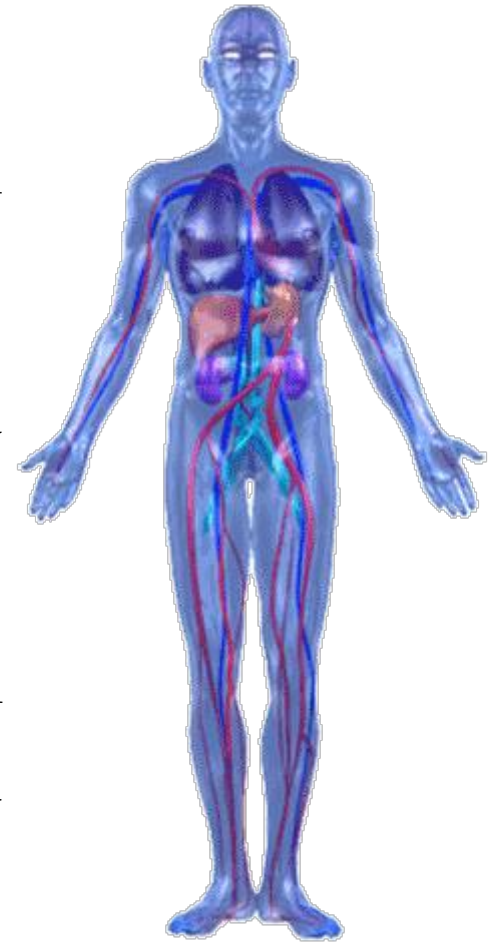
Anatomical terms

It is important for medical personnel to have a sound knowledge and understanding of the basic anatomic terms. The accurate use of anatomic terms by medical personnel enables them to communicate with their colleagues both nationally and internationally. Without anatomic terms, one cannot accurately discuss or record the abnormal functions of joints, the actions of muscles, the alteration of position of organs, or the exact location of swellings or tumors.

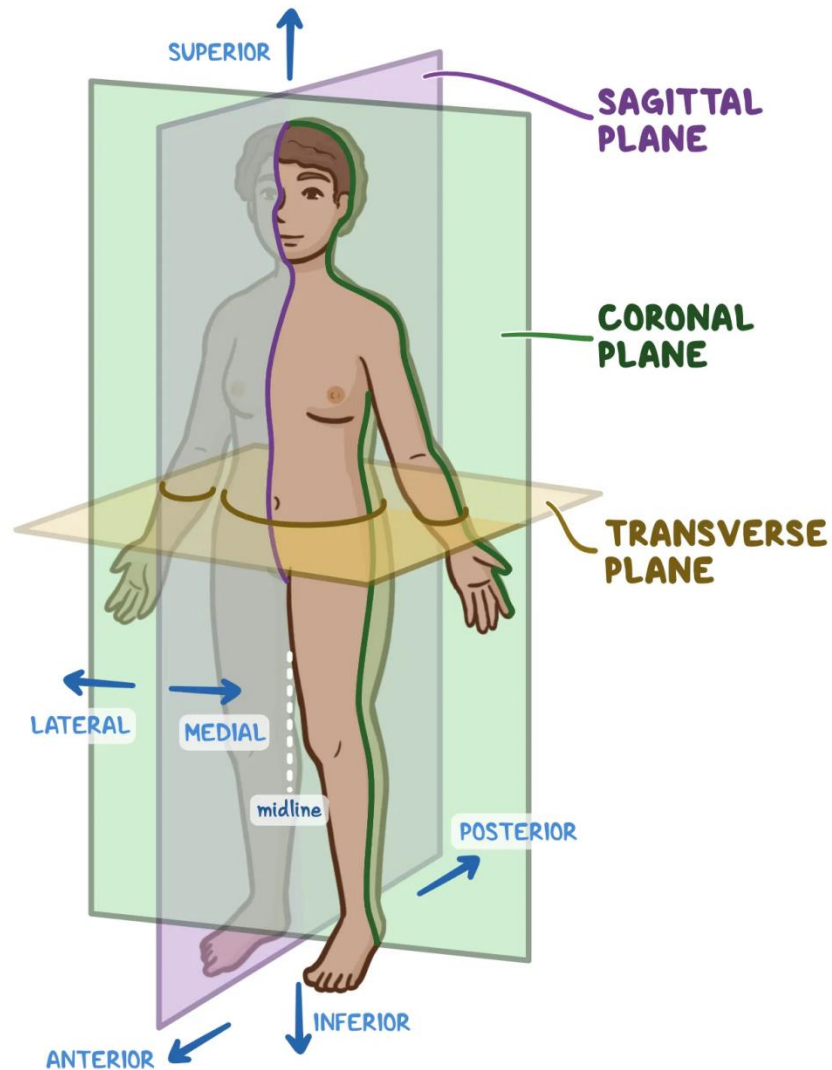
Terms related to Position

Anatomic position: All descriptions of the human body are based on the assumption that the person is standing erect, with the upper limbs by the sides and the face and palms of the hands directed forward.

The various parts of the body are then described in relation to certain imaginary planes.



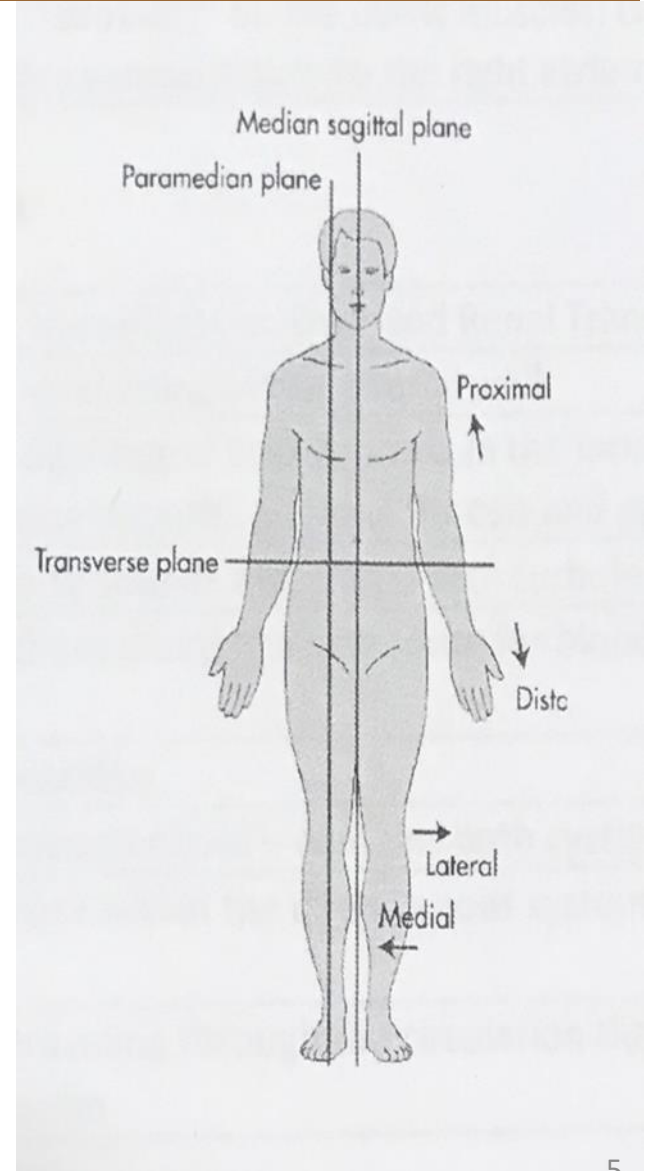
Anatomic position



Imaginary planes

The median sagittal plane.

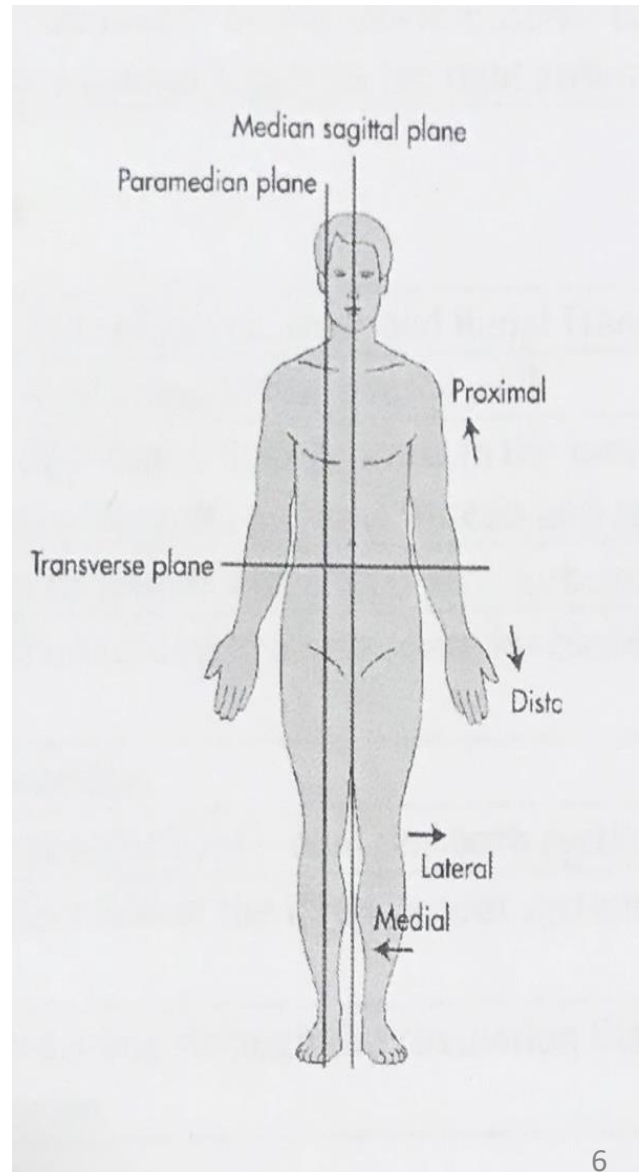
Is a vertical plane passing through the center of the body, dividing it into equal right and left halves.



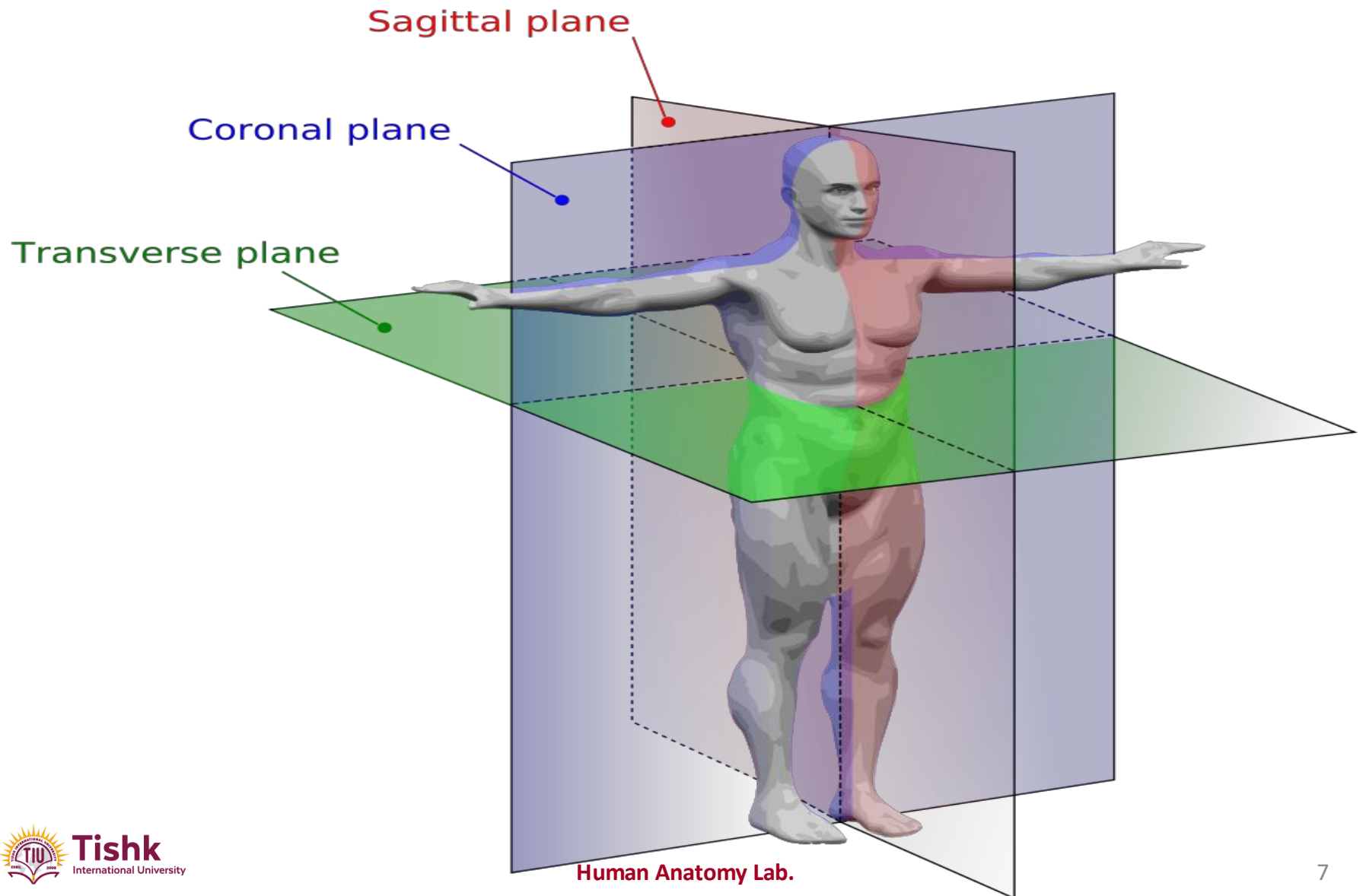
Paramedian planes

Paramedian planes:

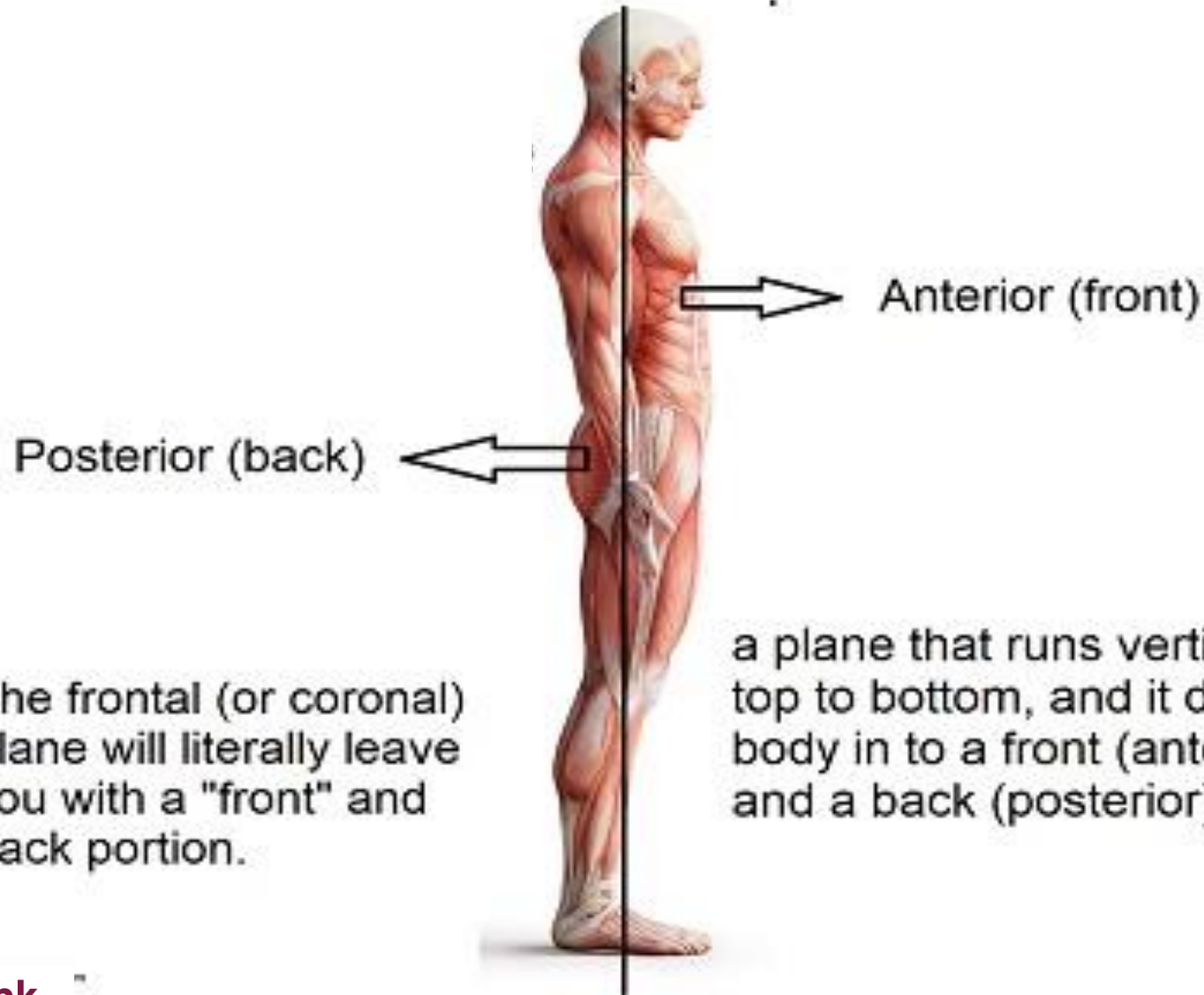
are planes situated to one or the other side of the median plane and parallel to it.



Body sections are divided by planes



Coronal Planes

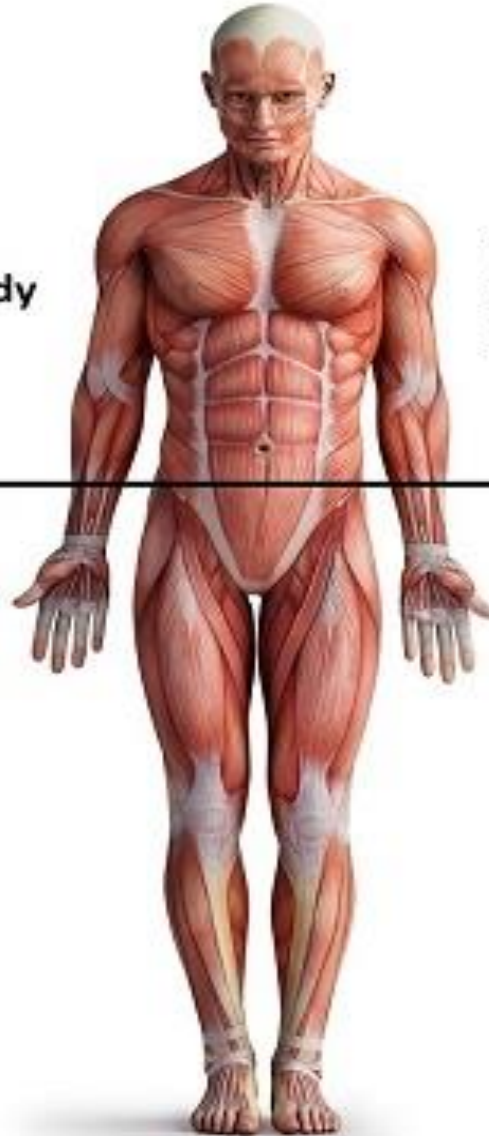


The frontal (or coronal) plane will literally leave you with a "front" and back portion.

a plane that runs vertically from top to bottom, and it divides the body in to a front (anterior) side and a back (posterior) side.

Horizontal planes

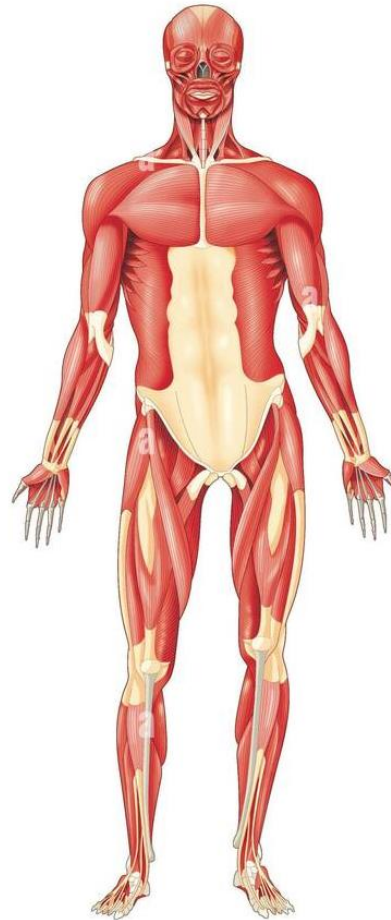
This is the only horizontal plane, and it divides the body into a top (superior) and bottom (inferior) portion.



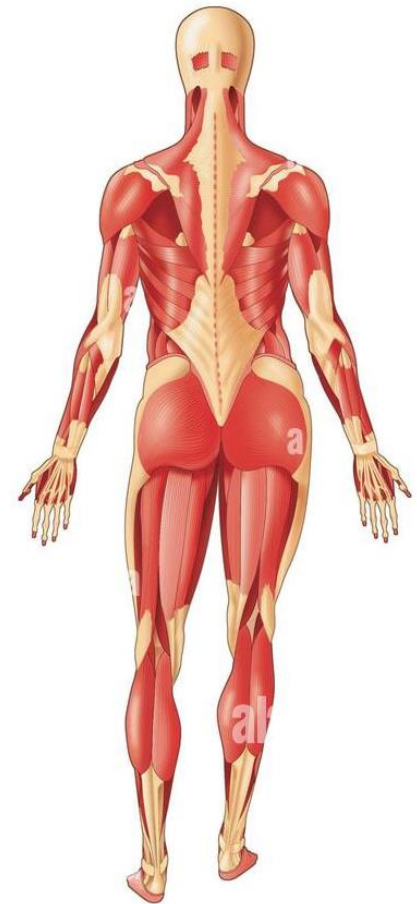Also called a horizontal plane, picture a horizon, and you'll remember this body plane.

Anterior and Posterior

Anterior and Posterior: these terms are used to indicate the front and back of the body respectively.



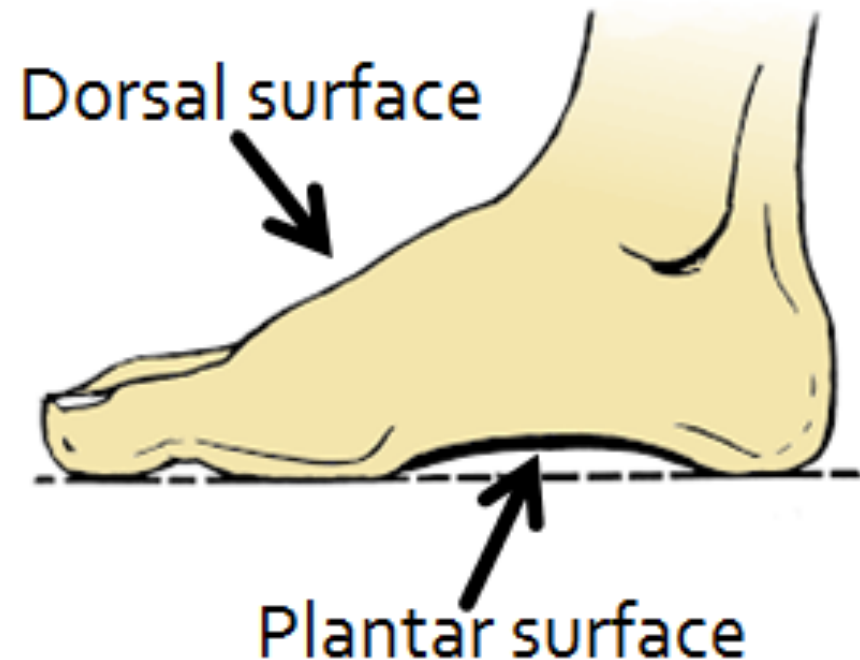
Anterior



Posterior

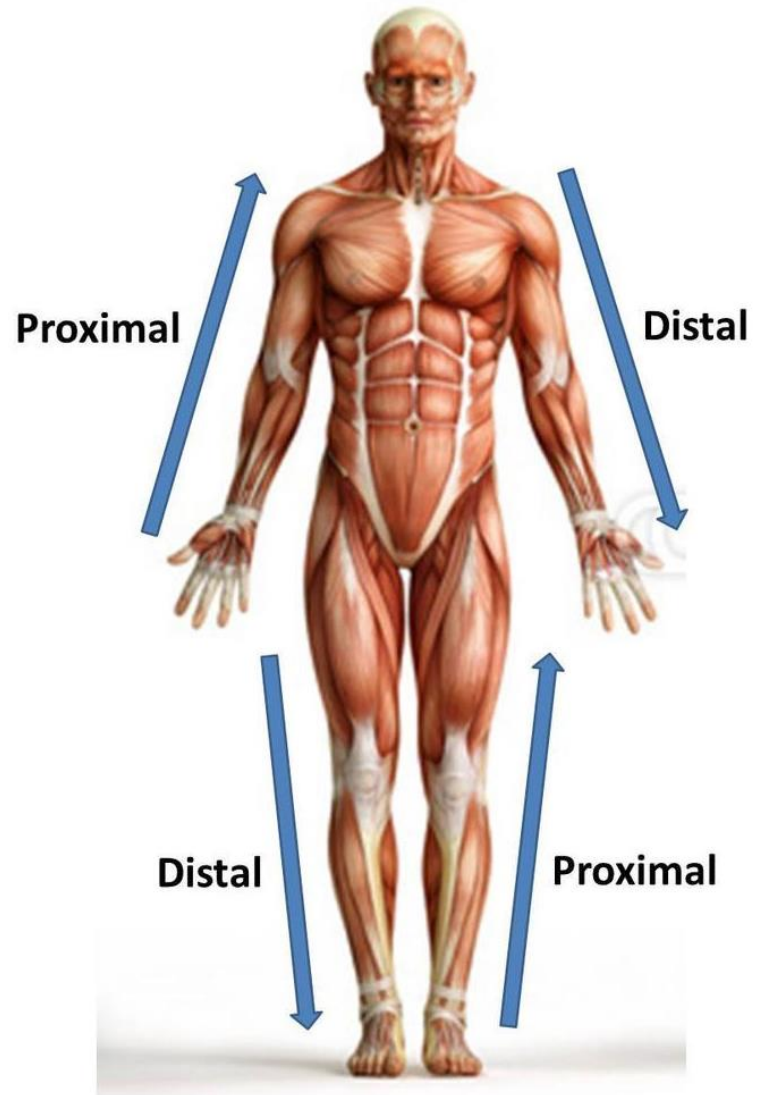
Anterior and Posterior

in describing the foot, the terms plantar and dorsal surfaces are used instead of lower and upper surfaces



Proximal and Distal

They describe the relative distances from the roots of the limbs.

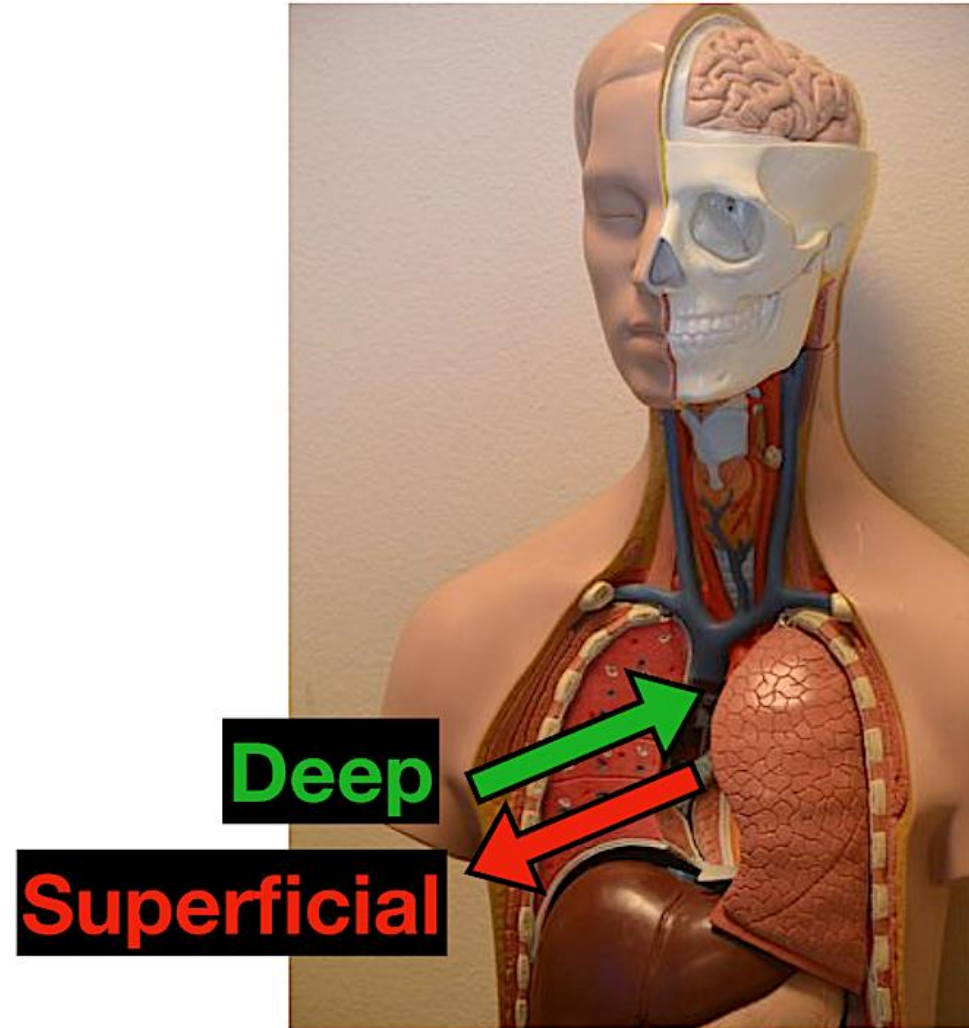


Superficial and Deep

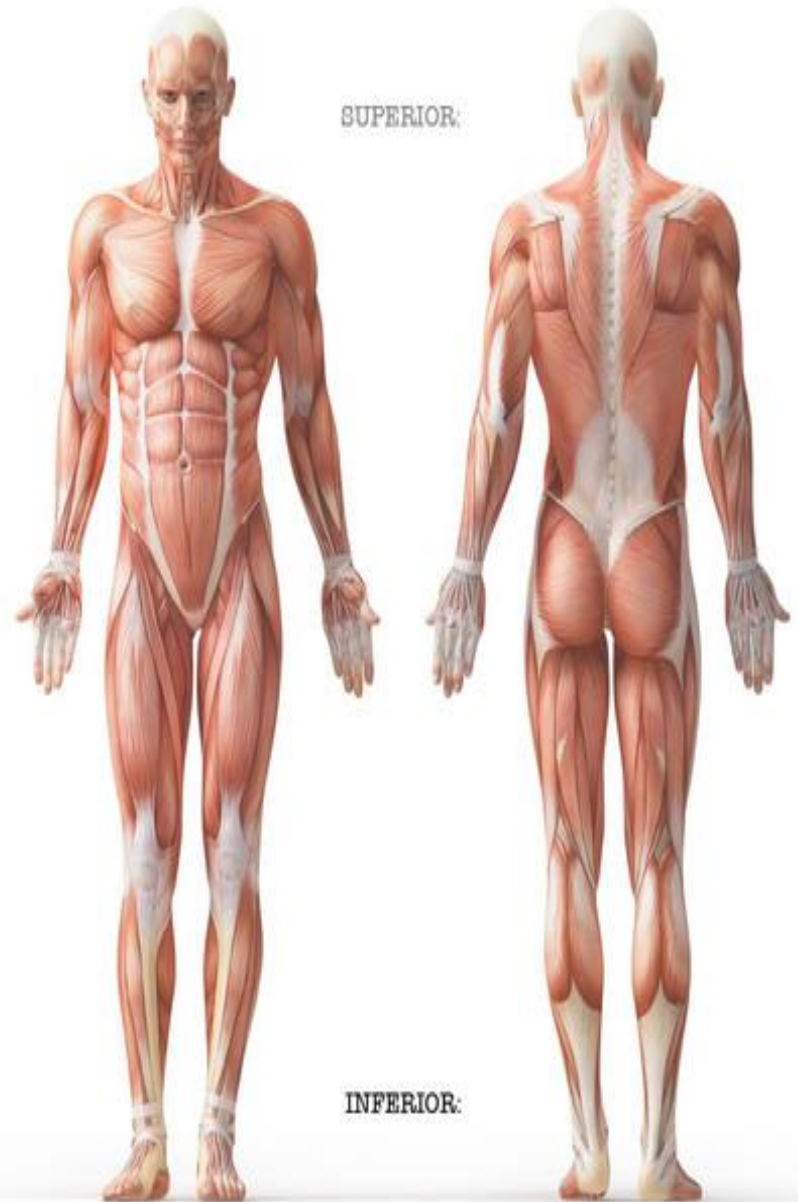Superficial = Closer to the surface of the body

Superficial = Surface

Deep = Away from the surface of the body

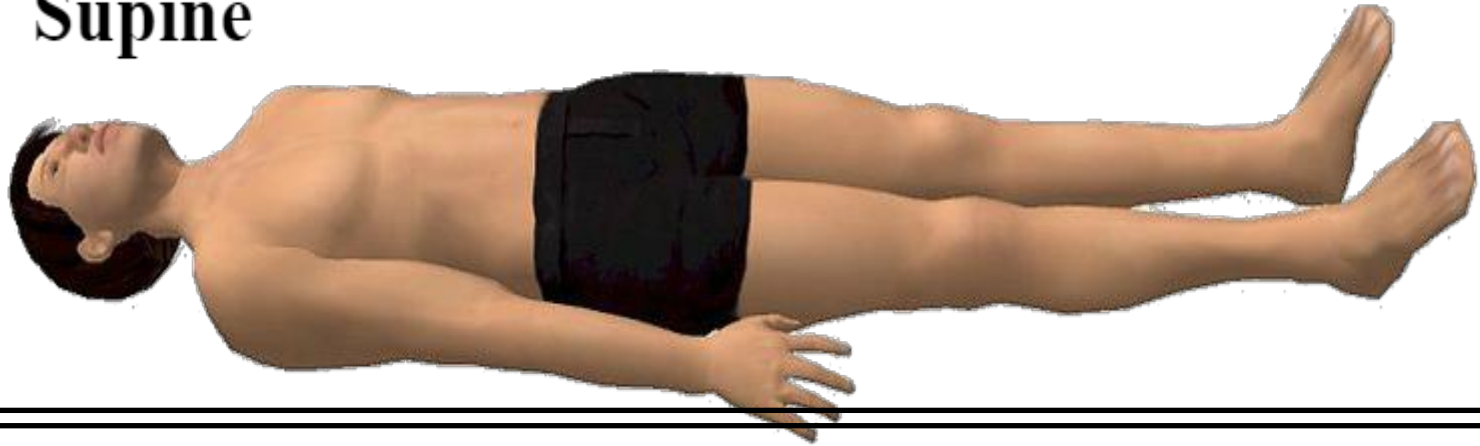


Superior and Inferior
demonstrate levels
relatively high or low
with reference to the
upper and lower ends
of the body

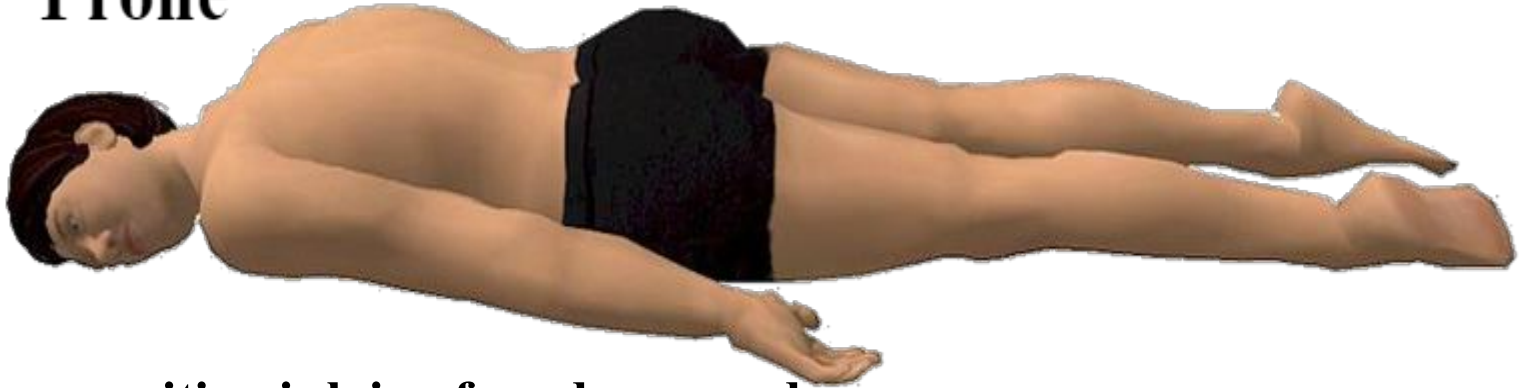

The Supine position of the body is lying on the back.

Supine



Prone

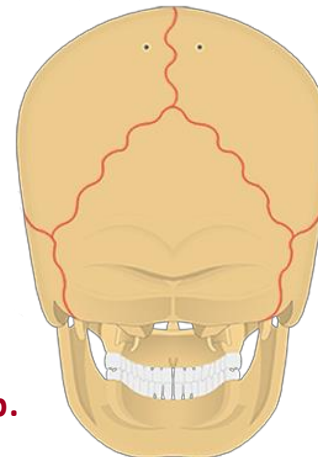
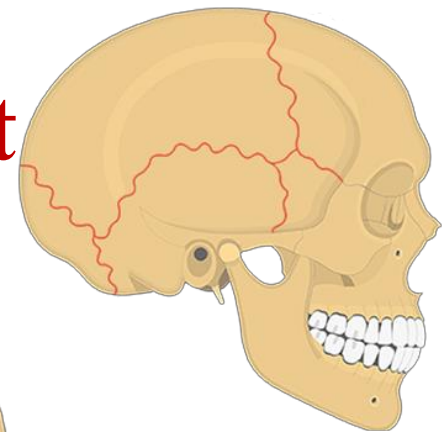


The prone position is lying face downward.

Terms related to Movement

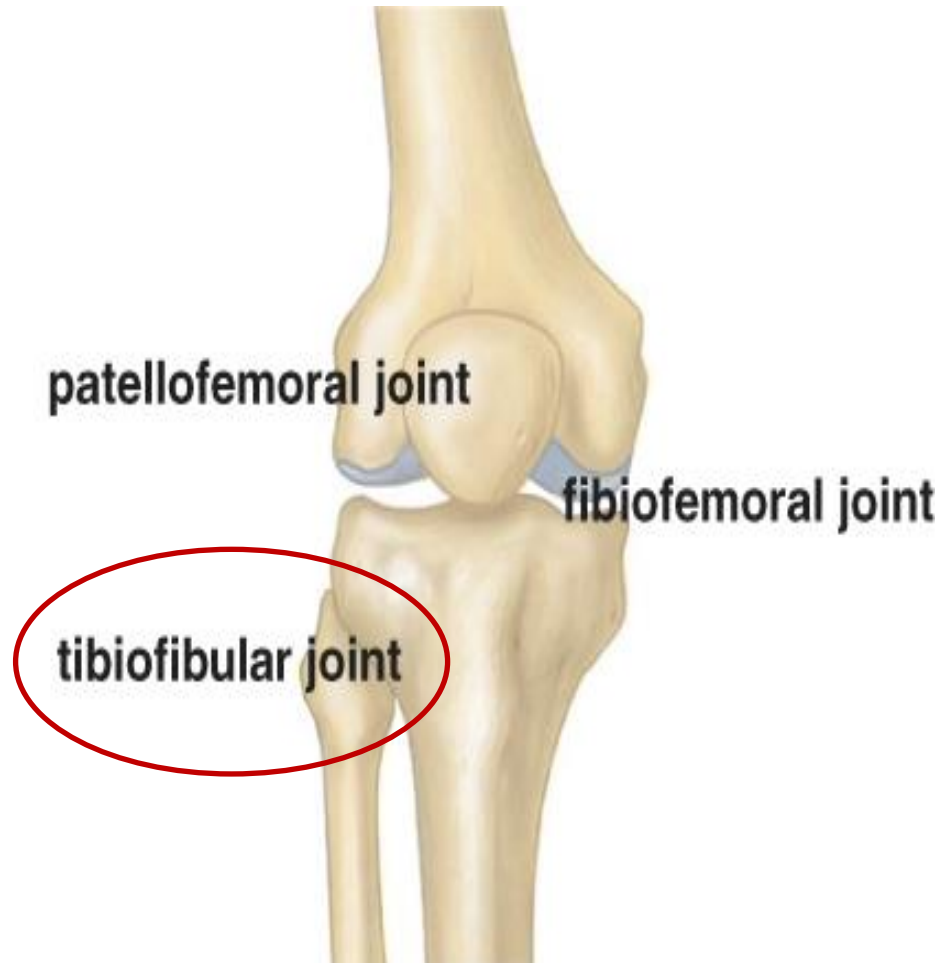
A site where two or more bones come together is known as a joint.

1. Some joints have no movement (sutures of the skull).



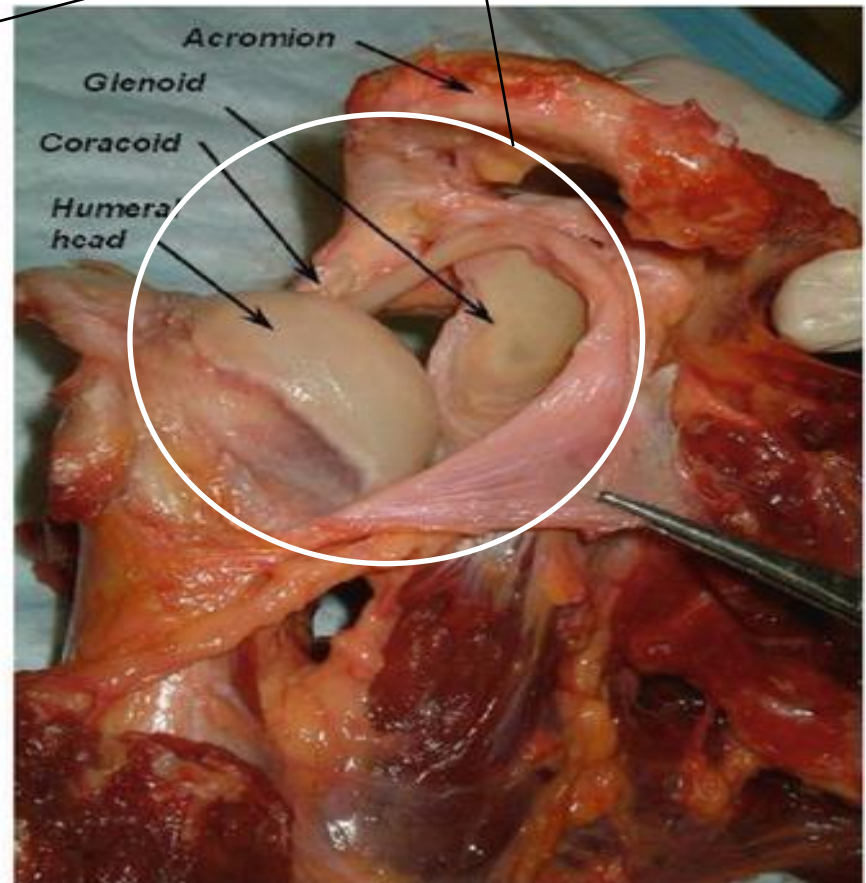
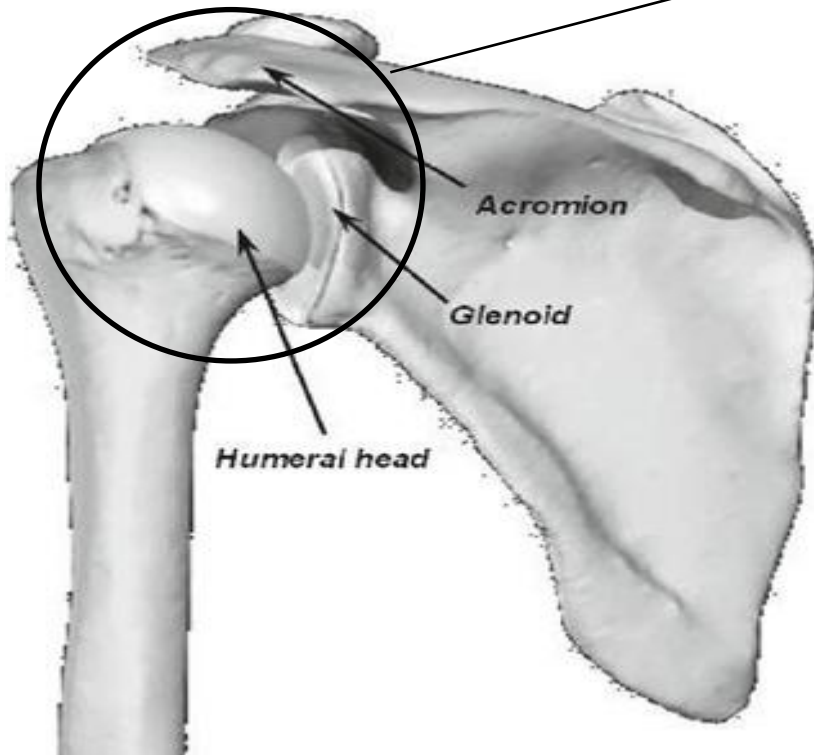Terms related to Movement

2. Some have only slight movement(tibiofibular joint)



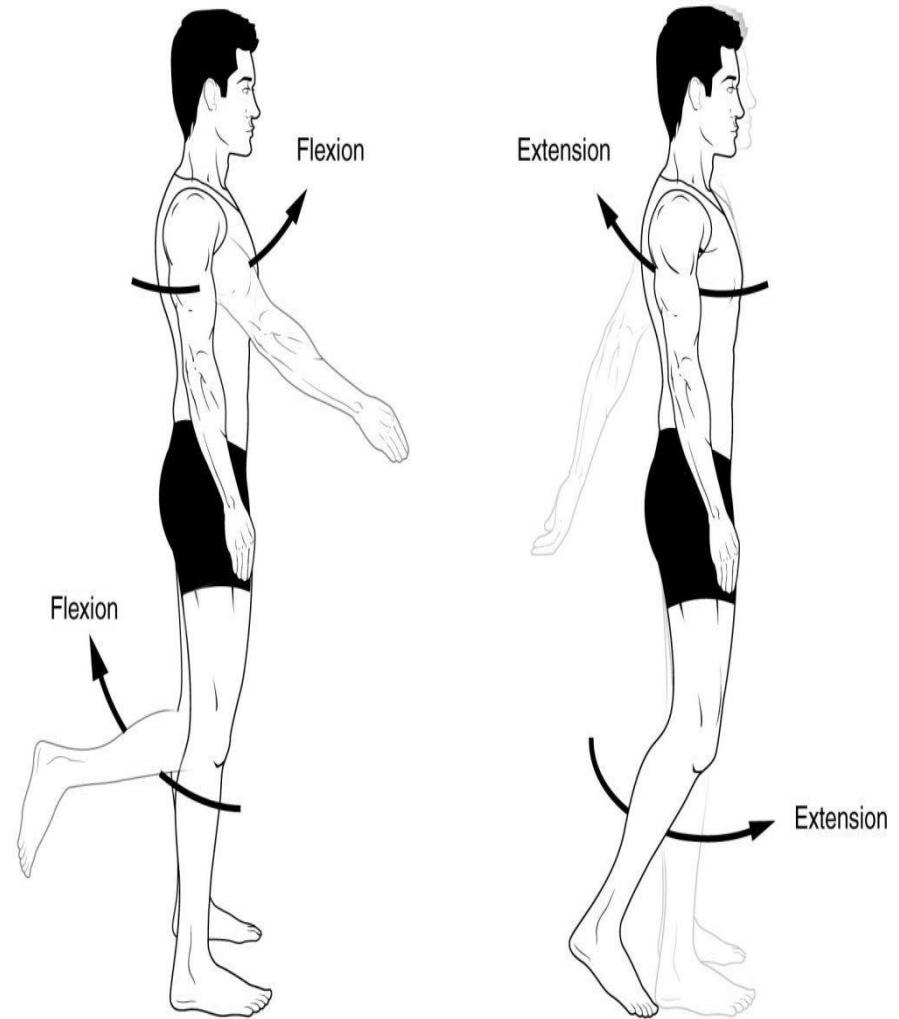
Terms related to Movement

3. Some are freely movable (shoulder joint)

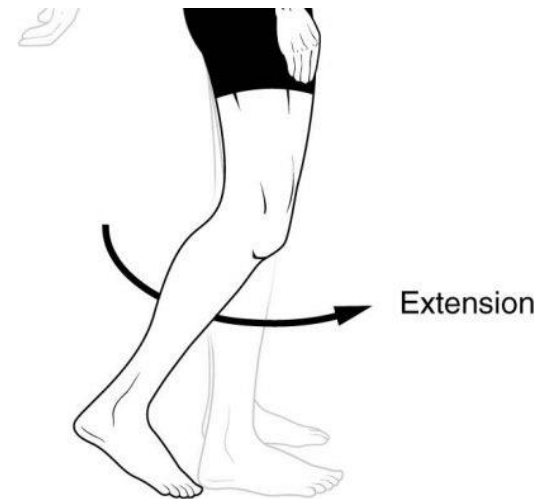
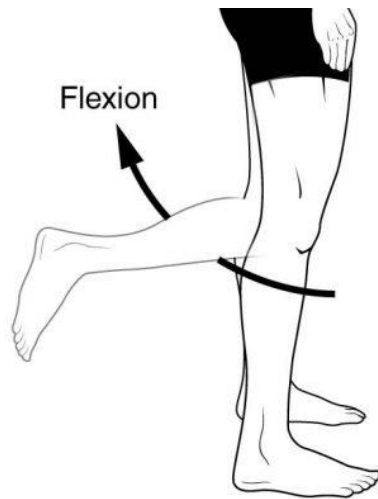


Flexion is a movement that takes place in a sagittal plane. For example, flexion of the elbow joint approximates the anterior surface of the forearm to the anterior surface of the arm.

It's usually an anterior movement, but it occasionally posterior, as in the case of the knee joint.

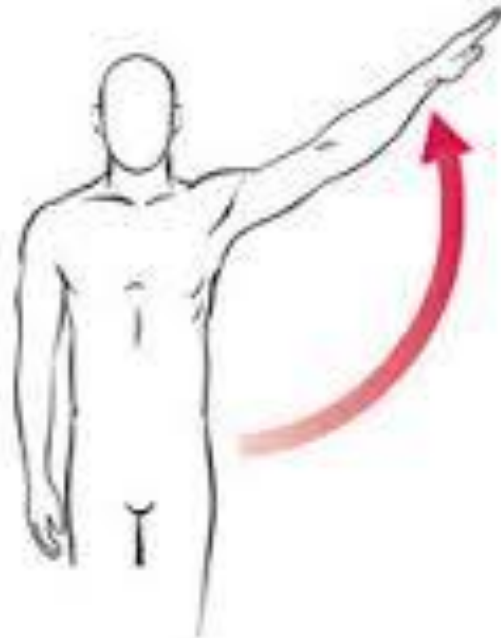


Extension means straightening the joint and usually takes place in a posterior direction.

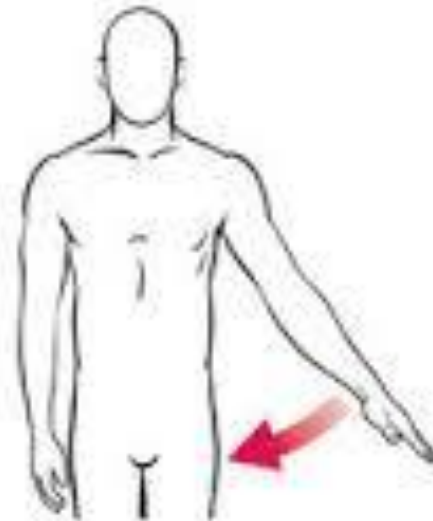


Lateral flexion is the movement of the trunk in the coronal plane.

Abduction of a limb is the movement away from the midline of the body in the coronal plane.



Shoulder abduction



Shoulder adduction

Adduction of a limb is the movement toward the body in the coronal plane.

